

EDITORIAL

More on the noninvasive diagnosis of pulmonary hypertension: Doppler echocardiography revisited

R. Naeije*, A. Torbicki**

The noninvasive diagnosis of pulmonary hypertension generally includes a physical examination, an electrocardiogram, a chest roentgenogram, a radionuclide angiography, and an echocardiography. These methods can discriminate mild from severe elevation in pressure, but lack sufficient sensitivity to be useful in the evaluation of short-term therapeutic interventions or in the monitoring of the clinical course of patients [1, 2]. Advances in echo-Doppler technology in the years since 1980 have made it possible to improve the estimation of pulmonary artery pressures (P_{pa}) and pulmonary vascular resistance (PVR) by the study of tricuspid regurgitation (TR) jets and pulmonary flow-velocity waves [3]. The echo-Doppler evaluation of pulmonary hypertension has since entered routine cardiological practice, but is still considered inferior to a right heart catheterization [4, 5]. This opinion may be based on an insufficient appreciation of the information content of the Doppler recordings.

Tricuspid regurgitation

The recording of TR jets by continuous wave Doppler echocardiography was first reported in 1984 by YOCK and POPP [6] in a series of 62 patients with clinical signs of right heart failure. These authors applied an idea previously proposed by SKJAERPE and HATLE [7], consisting of the calculation of a transtricuspid gradient (DP) from the maximum velocity (V) of TR jets using the simplified form of the Bernoulli equation: $DP \text{ (mmHg)} = 4 \times V^2 \text{ (m} \cdot \text{s}^{-1})$ (fig. 1). Adding the transtricuspid gradient to mean right atrial pressure (estimated clinically from the jugular veins) yielded predictions of right ventricular systolic pressures that were extremely close to those obtained with catheterization, even if not studied simultaneously [6]. This method has been widely used in patients with valvular, myocardial and congenital heart disease, with reported correlation coefficients between Doppler and catheter measurements ranging 0.89–0.97 [8–10]. The prediction of systolic right ventricular pressure or pulmonary artery pressure (P_{pa}) has been shown to be accurate over a wide range of pressures [6, 8–10], and not affected by the level of cardiac output [9]. The interobserver variability of the TR maximal velocity has been found to be less than

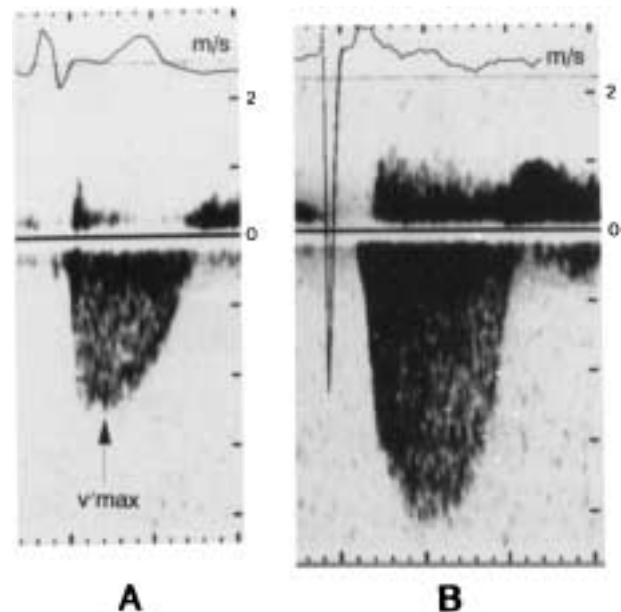


Fig. 1. – Doppler tricuspid regurgitation jets: A) in a patient without pulmonary hypertension; and B) in a patient with pulmonary hypertension. Estimated right arterial pressure were 5 and 15 mmHg, respectively, and calculated systolic pulmonary artery pressure 28 and 82 mmHg, respectively. Systolic pulmonary artery pressures measured with a Swan Ganz catheter were 27 and 79 mmHg, respectively. V_{max} : maximum velocity.

3% [9]. However, whilst a TR signal can be recorded in 90% [6] to 100% [9] of patients with clinical signs of right heart failure, and is almost invariably present with a systolic P_{pa} higher than 50 mmHg [8, 9], the recovery rate may decrease to 72% in the absence of clinical signs of right heart failure [10]. In series of patients with chronic obstructive pulmonary disease (COPD), lower recovery rates of TR jets of 66% [11], or even 24% [12] have been reported. It is possible to improve these excessively low recovery rates by the use of saline contrast enhancement [13]. Doppler echocardiography can detect TR in 50% of normal subjects [14]. This characteristic has been exploited for the noninvasive investigation of pulmonary vascular reactivity to hypoxia in normal men [15].

Compared to right heart catheterization measurements, the standard error for the estimate of Doppler TR-derived pressure calculation ranges 5–9 mmHg, which is in contrast to the above mentioned very high correlation coefficients [6, 8, 9, 11, 13]. This has been explained by nonsimultaneous invasive measurements,

*Dept of Intensive Care, Erasme University Hospital, Brussels, Belgium.

**Dept of Hypertension and Angiology, Medical Academy Warszawa, Warsaw, Poland.

clinical evaluation instead of direct measurement of right atrial pressure, some unavoidable beam to flow angle, and uncertainty in the assignment of maximum velocity in the regurgitant signal [6]. In addition, the maximum transtricuspid pressure gradient may occur before peak right ventricular systolic pressure in the presence of a prominent V wave in the right arterial pressure [6]. Also, most studies have correlated Doppler estimates of systolic right ventricular pressure to systolic P_{pa} , whilst there may be a pressure gradient between the right ventricle and the pulmonary artery. This gradient is more or less positive in early systole, but becomes more or less negative at a variable stage of systolic ejection, depending on type and severity of pulmonary hypertension [16]. It may be added that the frequency response of fluid-filled pulmonary artery catheters is inadequate for the measurement of instantaneous pressures. Finally, it was recently shown that in patients with severe pulmonary hypertension, Doppler TR jet-derived prediction of peak systolic right ventricular pressure may underestimate high fidelity transducer-tipped catheter pressure by an average of 20% [17]. The authors attributed this surprising finding to the tricuspid orifice geometry assumption on which the use of the simplified form of the Bernoulli equation is based [17].

How should a Doppler TR jet-derived estimation of a peak systolic transtricuspid pressure gradient be used? This pressure gradient rises in proportion to systolic P_{pa} , and is therefore useful as an indication of the severity of pulmonary hypertension. However, it is not possible to calculate a mean P_{pa} from a systolic P_{pa} , because, at a given mean P_{pa} or pulmonary vascular resistance (PVR), pulse pressure varies with pulmonary arterial compliance

and wave reflection depending on the type of pulmonary hypertension [18]. The peak systolic pressure is also of limited use in the evaluation of systolic right ventricular function. If afterload is defined as systolic ventricular wall tension, *i.e.*, by extrapolation of Laplace's law, the product of pressure by volume divided by wall thickness, the relevant pressure is in early systole, when volume is still close to its end-diastolic value [19]. If afterload is defined as the pulmonary arterial hydraulic load [19], the relevant pressure is the complete pressure wave which, together with the complete flow wave, can be analysed in the frequency domain for the calculation of the ratio of pulsatile pressure to pulsatile flow, or pulmonary vascular impedance [18]. Concerning contractility, for which the best possible index is maximal ventricular elastance (E_{max}), the ratio of pressure by volume around end-systole, the relevant pressure is end-systolic [19]. Some authors have estimated E_{max} by the ratio between peak systolic pressure and end-systolic volume [5], but the validity of this index of contractility is at best uncertain [19].

Pulmonary blood flow velocity

The application of a pulsed Doppler technique to record pulmonary artery flow velocity was reported in 1983 by KITABATAKE *et al.* [20] in a series of 33 patients, of whom 16 had a mean P_{pa} higher than 20 mmHg. In the patients with a normal P_{pa} , ejection flow velocity reached a peak level at mid-systole, producing a dome-like contour, whilst in the patients with pulmonary hypertension, the time to peak flow velocity (acceleration time (AT)) was decreased, producing a triangular contour (fig. 2). A secondary

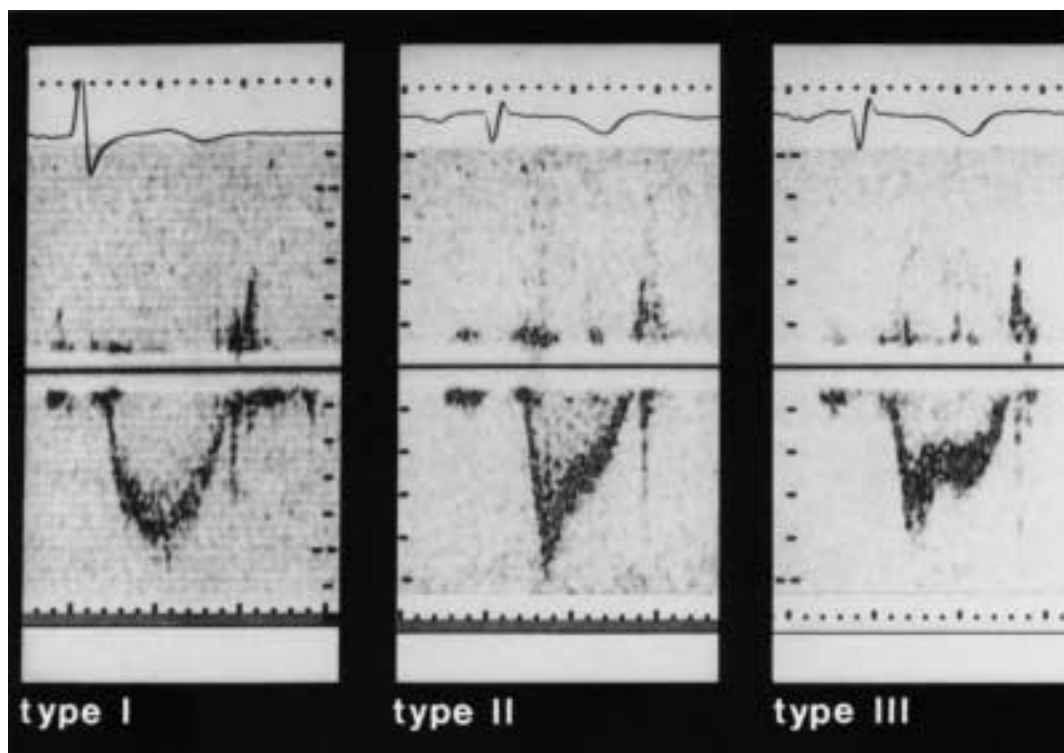


Fig. 2. — Doppler pulmonary flow velocity curves in a patient without pulmonary hypertension (Type I) and in two patients with pulmonary hypertension (Types II and III). Type I: normal, dome-like contour with a maximum velocity in the middle of systole. Type II: triangular contour, with a sharp peak in early systole, and a decreased acceleration time. Type III: similar to Type II, but with a mid-systolic notching.

slower rise was observed during deceleration in 10 patients, resulting in mid-systolic notching (fig. 2). A high correlation coefficient, around 0.9, was found between AT, or AT correlated for ejection time (ET), and mean P_{pa} .

Satisfactory Doppler recordings were obtained in 70% of patients referred to the catheterization laboratory. This proportion increased to 90% in patients with pulmonary hypertension. The study also showed a close correlation between pulmonic valve motion and pulmonary artery flow velocity pattern, but noted that mid-systolic notching was not always related to the severity of pulmonary hypertension, and could be intermittent [20].

Moderately good to excellent correlation coefficients, from 0.65–0.96, between AT alone or correlated for ET, pre-ejection time or heart rate and mean P_{pa} or PVR or their logarithms have been reported in many studies on patients with pulmonary hypertension of various severities and origins, but standard errors of the estimates have remained relatively high, up to 10 mmHg and sometimes more [10, 12, 20–28]. Furthermore, acute changes in P_{pa} induced by exercise, volume loading, oxygen or nifedipine administration, are only loosely correlated to inverse directional changes in AT [29]. Interobserver and intra-observer variabilities appear to be on average 9 and 7% respectively [27]. The recovery rate of pulmonary flow velocity curves ranges 81–98%, does not depend on the severity of pulmonary hypertension, and is not decreased in patients with COPD [10, 12, 20–28]. It is possible to attain a recovery rate of 100% in normal subjects [15].

What determines the shape of a pulmonary flow velocity curve? AT is not generally affected by tricuspid insufficiency, even at high levels of P_{pa} [10, 20, 24]. Severe right ventricular dysfunction prolongs AT [24]. Patients with an atrial septal defect and moderately

increased P_{pa} due to an increased pulmonary blood flow have a longer AT than patients with the same P_{pa} in the context of valvular heart disease [24]. The same increase in P_{pa} induced by passive leg rising shortens AT in patients with pulmonary hypertension due to COPD, but increases AT in patients with a normal P_{pa} [30]. This is in keeping with the observation by KITABATAKE *et al.* [20] on a patient with pulmonary hypertension and arrhythmia, in whom a mid-systolic deceleration in flow velocity occurred only with the largest stroke volumes [20]. That the shape of a flow velocity wave is not just determined by mean P_{pa} has been repeatedly suspected by several authors, who speculated on the effects of volume flow [23, 24], PVR [25], wave reflection [24], or pulmonary arterial elastance [24, 26]. With respect to the premature deceleration of pulmonary systolic flow, this has been tentatively explained either by an early return of reflected waves [24], or by a vortex phenomenon [31].

To investigate the mechanisms of mid-systolic deceleration of pulmonary blood flow in pulmonary hypertension in dogs, FURUNO *et al.* [32] compared the effects of various degrees of pulmonary hypertension induced either by proximal pulmonary artery constriction or embolization by 150 μ m glass beads on pulmonary vascular impedance [32]. At a comparable severity of pulmonary hypertension, as assessed by mean P_{pa} and PVR, pulmonary arterial constriction was associated with a larger pulse pressure and a higher characteristic impedance taken as an index of pulmonary arterial elastance (characteristic impedance is the ratio between inertance and compliance of the proximal pulmonary arterial tree). A mid-systolic deceleration of pulmonary blood flow could be identified in half of the dogs with pulmonary artery constriction, and this was demonstrated to be due

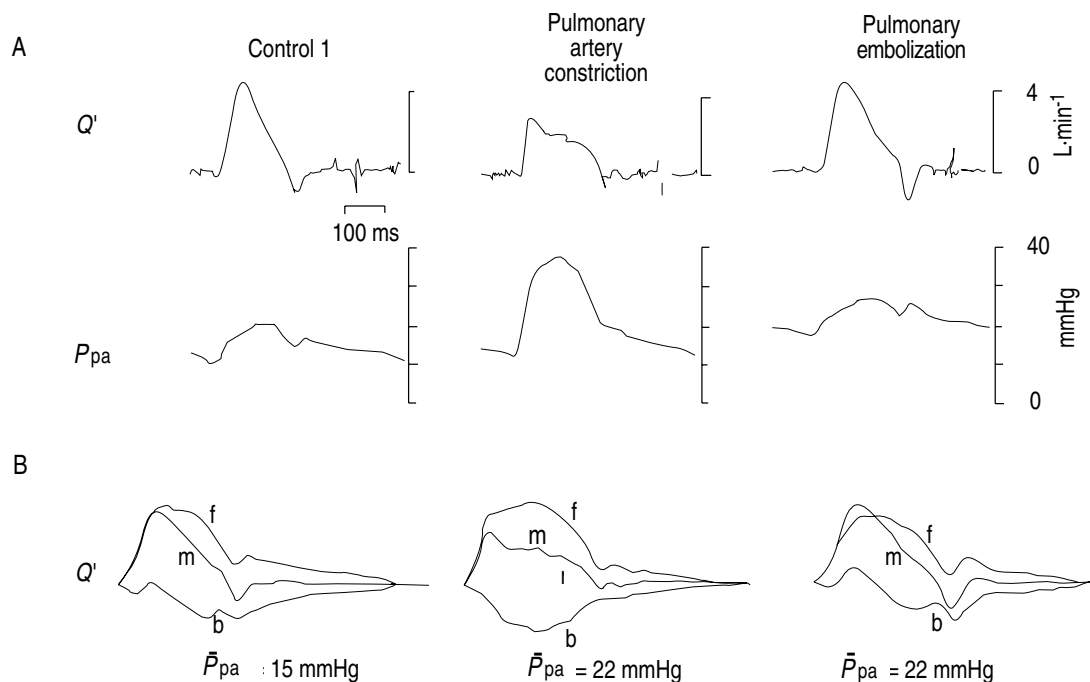


Fig. 3. — A) Pulmonary artery flow (Q') and pressure (P_{pa}) waves in a dog before (control) and after induction of pulmonary hypertension by either a proximal pulmonary artery constriction or injection of small 150 μ m glass beads. Constriction was associated with a higher pulse pressure and with a mid-systolic deceleration of flow due to an earlier return of the backward wave (see 3B). \bar{P}_{pa} : mean pulmonary artery pressure; f: forward; b: backward; m: resultant. (From [32], with permission).

to an earlier return of the backward flow wave (fig. 3). Pulmonary artery constriction was also associated with a shorter AT [32]. These findings are in keeping with earlier studies on pulsatile pulmonary haemodynamics, which established that the shape of arterial pressure and flow waves is determined by a dynamic interplay between resistance, elastance and wave reflection [18].

Echo-Doppler versus right heart catheterization

In clinical practice, right heart catheterization is almost always performed with fluid-filled thermodilution catheters. The inherent methodological limitation of this approach is that only mean pressures and mean flows can be measured. A thermodilution pulmonary blood flow determination necessarily covers several cardiac cycles, and the frequency response of fluid-filled catheters is inadequate for the measurement of instantaneous pressures. Thus, current methodology of invasive pulmonary haemodynamic studies neglects the natural pulsatility of the pulmonary circulation. In addition, these studies very often include the calculation of PVR to evaluate the severity of pulmonary hypertension and the effects of treatments. This is misleading for two reasons. Firstly, PVR is a flow-dependent variable, and therefore cannot be used to evaluate changes in pulmonary vascular tone at variable mean flow [33]. Secondly, PVR gives an incomplete description of the forces that oppose pulmonary arterial flow, that is pulmonary vascular impedance [34]. Thus, mean P_{pa} and PVR derived from a fluid-filled thermodilution catheter should not be taken as a gold standard for noninvasive beat-by-beat measurements.

What is the information content of a pulmonary flow velocity wave? The shape of flow velocity and flow volume waves is similar, but flow velocity cannot be equated with flow volume. Thus, the measurement cannot be used for the calculation of PVR, should this be needed. On the other hand, because AT is determined not only by mean P_{pa} and PVR, but also by pulmonary arterial elastance and wave reflection, it provides information about the hydraulic load imposed on the right ventricle.

Perspective

More studies are needed on the pulsatile haemodynamic correlates of pulmonary flow velocity in various types of pulmonary hypertension. Reports on the effects of physiological and pharmacological interventions have been, until now, surprisingly scarce. It is a reasonable speculation that echo-Doppler studies could help to explain why clinical signs of right ventricular failure are so variable in patients with the same severity of pulmonary hypertension as assessed by mean P_{pa} or PVR. Along the same line, the echo-Doppler approach should be added to routine right heart catheterization for an improved understanding of the effects of pulmonary vasodilators on right ventricular afterload. After a decade of sterile comparisons, it may be time to realize that the two methods do not compete, but complement each other.

References

- Weitzenblum E, Zielinski J, Bishop JM. The diagnosis of "cor pulmonale" by noninvasive methods: a challenge for pulmonologists and cardiologists. *Bull Eur Physio-pathol Respir* 1983; 19: 423–426.
- Reeves JT, Groves BM. Approach to the patient with pulmonary hypertension. In: Weir EK, Reeves JT eds. *Pulmonary Hypertension*. Mount Kisco, New York, Futura Publishing Co. Inc., 1984.
- Hatle L, Angelsen B. In: *Doppler Ultrasound in Cardiology: Physical Principles and Clinical Application*. 2nd edn. Philadelphia, Lea and Febiger, 1985; pp. 170–176 and 256–264.
- Weitzenblum E, Oswald M, Oswald T, Apprill M. Noninvasive diagnosis of pulmonary hypertension in chronic lung disease. In: Wagenvoort CA, Denolin H, eds. *Pulmonary Circulation: Advances and Controversies*. Amsterdam, Elsevier, 1989.
- MacNee W. Pathophysiology of cor pulmonale in chronic obstructive pulmonary disease. *Am J Respir Crit Care Med* 1994; 150: 833–853.
- Yock PG, Popp RL. Noninvasive estimation of right ventricular systolic pressure by Doppler ultrasound in patients with tricuspid regurgitation. *Circulation* 1984; 70: 657–662.
- Skjaerpe T, Hatle L. Diagnosis and assessment of tricuspid regurgitation with Doppler ultrasound. In: Risterborgh H, ed. *Echocardiology*. The Hague, Marinus Nijhoff, 1981; pp. 299–304.
- Berger M, Haimowitz A, Von Tosh A, Berdoff RL, Goldberg E. Quantitative assessment of pulmonary hypertension in patients with tricuspid regurgitation using continuous wave Doppler ultrasound. *J Am Coll Cardiol* 1985; 6: 359–365.
- Currie PJ, Seward JB, Chan KL, *et al.* Continuous wave Doppler determination of right ventricular pressure: a simultaneous Doppler-catheterization study in 127 patients. *J Am Coll Cardiol* 1985; 6: 750–756.
- Chan KL, Currie PJ, Seward JB, Hagler DJ, Mair DD, Tajik AJ. Comparison of three ultrasound methods in the prediction of pulmonary artery pressure. *J Am Coll Cardiol* 1987; 9: 549–554.
- Laaban JP, Diebold B, Zielinski R, Lafay M, Raffoul H, Rochemaure J. Noninvasive estimation of systolic pulmonary artery pressure using Doppler echocardiography in patients with chronic obstructive pulmonary disease. *Chest* 1989; 96: 1258–1262.
- Torbicki A, Skwarski K, Hawrylkiewicz I, Pasiński T, Miskiewicz Z, Zielinski J. Attempts at measuring pulmonary arterial pressure by means of Doppler echocardiography in patients with chronic lung disease. *Eur Respir J* 1989; 2: 856–860.
- Himmelman RB, Stulbarg M, Kircher B, *et al.* Non-invasive evaluation of pulmonary artery pressure during exercise by saline-enhanced Doppler echocardiography in chronic pulmonary disease. *Circulation* 1989; 79: 863–871.
- Berger M, Hecht SR, Van Tosh A, Lingam U. Pulsed and continuous wave Doppler echocardiographic assessment of valvular regurgitation in normal subjects. *J Am Coll Cardiol* 1989; 13: 1540–1545.
- Vachiéry JL, McDonagh T, Moraine JJ, *et al.* Doppler assessment of hypoxic pulmonary vasoconstriction and susceptibility to high-altitude pulmonary edema. *Thorax* 1995; 50: 22–27.
- Tahara M, Tanaka H, Nakao S, *et al.* Hemodynamic determinants of pulmonary valve motion during systole

- in experimental pulmonary hypertension. *Circulation* 1981; 64: 1249–1255.
17. Brecker SJD, Gibbs JSR, Fox KM, Yacoub MH, Gibson DG. Comparison of Doppler derived haemodynamic variables and simultaneous high fidelity pressure measurements in severe pulmonary hypertension. *Br Heart J* 1994; 72: 384–389.
 18. MacDonald's Blood Flow in Arteries. In: Nichols WW, O'Rourke MF, eds. 3rd edn. London, Edward Arnold 1990.
 19. Maughan WL, Oikawa RY. Right ventricular function. In: Scharf SM, Cassidy SS, eds. Heart-Lung Interactions in Health and Disease. Lung Biology in Health and Disease. Executive Editor, C. Lenfant. New York, Marcel Dekker, Inc., 1989; pp. 179–220.
 20. Kitabatake A, Inoue M, Asao M, *et al.* Noninvasive evaluation of pulmonary hypertension by a pulsed Doppler technique. *Circulation* 1983; 68: 302–309.
 21. Kosturakis D, Goldberg S, Allen HD, Leber C. Doppler echocardiographic prediction of pulmonary arterial hypertension in congenital heart disease. *Am J Cardiol* 1984; 53: 1110–1115.
 22. Zeiher AM, Bonzel T, Wollschläger H, Hohnloser S, Hust MH, Just H. Noninvasive evaluation of pulmonary hypertension by quantitative contrast M-mode echocardiography. *Am Heart J* 1986; 111: 297–306.
 23. Isobe M, Yazaki Y, Takaku F, *et al.* Prediction of pulmonary arterial pressure in adults by pulsed Doppler echocardiography. *Am J Cardiol* 1986; 57: 315–321.
 24. Matsuda M, Sekiguchi T, Sugishita Y, Kuwako K, Iida K, Ito I. Reliability of noninvasive estimates of pulmonary hypertension by pulsed Doppler echocardiography. *Br Heart J* 1986; 56: 58–64.
 25. Martin-Duran R, Larman M, Trugeda A, *et al.* Comparison of Doppler-determined elevated pulmonary arterial pressure with pressure measured at cardiac catheterization. *Am J Cardiol* 1986; 57: 859–863.
 26. Marchandise B, De Bruyne B, Delaunois L, Kremer R. Noninvasive prediction of pulmonary hypertension in chronic obstructive pulmonary disease by Doppler echocardiography. *Chest* 1987; 91: 361–365.
 27. Dabestani A, Mahan G, Gardin JM, *et al.* Evaluation of pulmonary artery pressure in adults by pulsed Doppler technique. *Am J Cardiol* 1987; 59: 662–668.
 28. Miguerez M, Escamilla R, Coca F, Didier A, Krempf M. Pulsed Doppler echocardiography in the diagnosis of pulmonary hypertension in COPD. *Chest* 1990; 98: 280–285.
 29. Torbicki A, Tramarin R, Fracchia C, *et al.* Reliability of pulsed wave Doppler monitoring of acute changes in pulmonary artery pressure in patients with chronic obstructive pulmonary disease. *Prog Respir Res* 1990; 26: 133–141.
 30. Torbicki A, Tramarin R, Fracchia C, *et al.* Effect of increased right ventricular afterload on pulmonary artery flow velocity pattern in patients with normal or increased pulmonary artery pressure. *Am J Noninvasive Cardiol* 1994; 8: 151–155.
 31. Okamoto M, Miyatake K, Kinoshita N, Sakakibara H, Nimura Y. Analysis of blood flow in pulmonary hypertension with the pulsed Doppler flow meter combined with cross-sectional echocardiography. *Br Heart J* 1984; 51: 407–415.
 32. Furuno Y, Nagamoto Y, Fujita M, Kaku T, Sakurai S, Kuroiwa A. Reflection as a cause of mid-systolic deceleration of pulmonary flow wave in dogs with acute pulmonary hypertension: comparison of pulmonary artery constriction with pulmonary embolisation. *Cardiovasc Res* 1991; 25: 118–124.
 33. McGregor M, Sniderman A. On pulmonary vascular resistance: the need for more precise definition. *Am J Cardiol* 1985; 55: 217–223.
 34. Sniderman AD, Fitchett DH. Vasodilators and pulmonary hypertension. *Int J Cardiol* 1988; 20: 173–181.