

Pulmonary involvement in human T-cell lymphotropic virus type-I uveitis: T-lymphocytosis and high proviral DNA load in bronchoalveolar lavage fluid

M. Sugimoto*, S. Mita*, M. Tokunaga*, K. Yamaguchi**, I. Cho*,
M. Matsumoto*, M. Mochizuki†, S. Araki†, K. Takatsuki**, M. Ando*

Pulmonary involvement in human T-cell lymphotropic virus type-I uveitis: T-lymphocytosis and high proviral DNA load in bronchoalveolar lavage fluid. M. Sugimoto, S. Mita, M. Tokunaga, K. Yamaguchi, I. Cho, M. Matsumoto, M. Mochizuki, S. Araki, K. Takatsuki, M. Ando. ©ERS Journals Ltd 1993.

ABSTRACT: The ocular manifestation of human T-cell lymphotropic virus type I (HTLV-I) infection has been recognized as a new clinical entity termed HTLV-I uveitis. In order to determine whether HTLV-I uveitis is associated with lymphocyte alveolitis, bronchoalveolar lavage (BAL) was carried out in 11 patients with HTLV-I uveitis, five asymptomatic HTLV-I carriers, 11 HTLV-I-negative patients with ocular sarcoidosis, and nine normal control subjects seronegative for HTLV-I.

Six of the 11 patients with HTLV-I uveitis showed increased total cell counts, and T-lymphocytosis in BAL fluid. CD4+/CD8+ ratios of T-lymphocytes were decreased in three of these patients, and normal in three other patients. Such abnormalities of the lung were not found in asymptomatic HTLV-I carriers, and in normal control subjects. BAL findings in HTLV-I uveitis differed from those of patients with sarcoidosis in terms of the lymphocytic component. Interestingly, it was found that there was an increase of HTLV-I proviral deoxyribonucleic acid (DNA) load in peripheral blood mononuclear cells (PBMC) from seven patients with HTLV-I uveitis, and in the BAL cells from four patients with pulmonary involvement.

These results provide further evidence in terms of HTLV-I tropism for the lung, and suggest that a systemic and local increase of HTLV-I proviral DNA load plays an important role in the pathogenesis of lymphocyte alveolitis in patients with HTLV-I uveitis.

Eur Respir J., 1993, 6, 938-943.

Human T-cell lymphotropic virus type I (HTLV-I) infection is endemic in tropical areas [1-3], and in southwestern Japan [4, 5], and has now been identified in the United States [6] and some European countries [7, 8]. HTLV-I is an aetiological retrovirus of adult T-cell leukaemia/lymphoma (ATL) [9, 10], and is also associated with a nonmalignant neurological disorder termed HTLV-I associated myelopathy/tropical spastic paraparesis (HAM/TSP) [2, 4, 11].

Uveitis is a major ocular manifestation, associated with infectious (tuberculosis, syphilis, toxoplasmosis, etc.), or non-infectious (sarcoidosis, Behcet's disease, Vogt-Koyanagi-Harada's disease, etc.) diseases [12]. Recently, based on clinical, seroepidemiological and virological studies, MOCHIZUKI and co-workers [13-15] showed that an intermediate uveitis, of unknown cause, was closely related to HTLV-I infection. This type of uveitis differs from the ocular manifestation of Behcet's disease, Vogt-Koyanagi-Harada's disease, cytomegalovirus infection and toxoplasmosis, and has now been recognized as a new clinical entity termed HTLV-I uveitis [15]. A similar ocular manifestation has occasionally been reported in patients

with HAM/TSP, and HTLV-I carriers without systemic disease [16, 17]. These reports prompted us to determine whether or not pulmonary involvement occurred in patients with HTLV-I uveitis, because HTLV-I has a peculiar tropism for the lung, as demonstrated in patients with HAM/TSP [18-20], and patients with ATL [21].

At present, the mechanisms by which HTLV-I uveitis is induced are completely unknown. In patients with HAM/TSP, however, cytological, immunological and virological analyses of bronchoalveolar lavage (BAL) cells have been shown to be helpful for understanding not only the pathogenesis of T-lymphocyte alveolitis, but also the pathogenesis of spastic paraparesis [20, 22]. In this context, the present study had two objectives. The first objective was to determine whether there was pulmonary involvement in patients with HTLV-I uveitis. The second objective was to determine, using polymerase chain reaction (PCR), whether HTLV-I proviral deoxyribonucleic acid (DNA) load was increased in patients with HTLV-I uveitis. We show here that bronchoalveolar T-lymphocytosis is found in patients with HTLV-I uveitis, and that

* The First Dept and ** The Second Dept of Medicine, Kumamoto University School of Medicine, Kumamoto, Japan. † Dept of Ophthalmology, Kurume University School of Medicine, Kurume, Fukuoka, Japan.

Correspondence: M. Sugimoto
The First Department of Internal Medicine
Kumamoto University School of Medicine
1-1-1 Honjo
Kumamoto 860
Japan

Keywords: Bronchoalveolar lavage
human T-cell lymphotropic virus type-I-
infected cells
HTLV-I uveitis
T-lymphocyte alveolitis

Received: September 21 1992
Accepted after revision February 18 1993

HTLV-I-infected cells are increased in the peripheral blood and the lower respiratory tract of these patients with pulmonary involvement.

Materials and methods

Study populations

Patients with HTLV-I uveitis consisted of seven females and four males, aged 49±10 yrs. A diagnosis of HTLV-I uveitis was established, according to the criteria described by MOCHIZUKI and co-workers [13, 15]. Background data of patients with HTLV-I uveitis are shown in table 1. Antibody titres to HTLV-I in serum were 512 to 4,096× when determined by gelatin particle agglutination (PA) method [23]. HTLV-I infection was confirmed by enzyme immunoassay (A-test ATL, Eisai Co., Tokyo, Japan), and Western blot analysis using lysate antigens of HTLV-I-producing MT2 cells. All patients with HTLV-I uveitis showed normal leucocyte counts in peripheral blood, and leukaemic cells were not found. Two patients (cases no. 8 and 9) have been treated with oral prednisolone (10–25 mg·day⁻¹).

The following subjects served as HTLV-I-positive or HTLV-I-negative controls; five asymptomatic HTLV-I carriers (four females and one male, aged 54±8 yrs, serum titres of antibody to HTLV-I: 128 to 2,048×), 11 HTLV-I-negative patients with uveitis and histologically-proven pulmonary sarcoidosis (six males and five females, mean age 35±11 yrs) and nine HTLV-I-negative healthy volunteers (all males, mean age 27±2.2 yrs of age). There were two smokers amongst the patients with HTLV-I uveitis (cases no. 10 and 11 in table 1) and two smokers amongst the patients with sarcoidosis.

Bronchoalveolar lavage

After obtaining informed consent from the patients, BAL was performed at the right middle lobe, using a

Table 1. – Background data of patients with HTLV-I uveitis

Case no.	Age yrs	Sex	Antibody titres to HTLV-I (Serum)	Western blotting	WBC cells·mm ⁻³
1	56	F	4,096×	+	5,400
2	60	F	1,024×	+	5,800
3	48	F	1,024×	+	6,600
4	51	F	2,048×	+	5,800
5	53	F	4,096×	+	6,200
6	50	F	1,024×	+	5,600
7	60	F	4,096×	+	4,500
8*	43	M	1,024×	+	5,700
9 [‡]	56	M	512×	+	5,600
10*	25	M	1,024×	+	5,400
11*	40	M	4,096×	+	4,700

Antibody titres to HTLV-I were measured by particle agglutination method and HTLV-I infection was confirmed by Western blotting. Cases no. 2 and 10 were associated with hyperthyroidism. *: prednisolone 10 mg·day⁻¹; [‡]: prednisolone 25 mg·day⁻¹. *: current smokers; +: presence of multiple bands including p19, p24 or p28; HTLV-I: human T-cell lymphotropic virus type-1; WBC: white blood cells.

flexible fibreoptic bronchoscope and 150 ml of sterile saline, as reported previously [20].

The collected BAL fluid was passed through two sheets of sterile gauze, and centrifuged at 400×g for 10 min at 4°C. After washing twice with Hanks' balanced salt solution, total cells were counted using a haemocytometer, and collected to extract genomic DNA. An aliquot of the cell suspensions was smeared onto glass, using a cytocentrifuge apparatus (Tomy Seiko Co., Tokyo, Japan), and stained with Diff-Quik (Kokusai Shinyaku Co., Kobe, Japan) for determination of differential cell counts.

Preparation of lymphocyte-rich and macrophage-rich populations

The entire BAL cell suspensions (10⁶ cells·ml⁻¹ in RPMI 1640) were incubated at 37°C for 60 min in 90×20 mm plastic dishes (Falcon). Nonadherent cells were removed by brisk agitation and washing five times with warm RPMI 1640. Nonadherent cells were used as the lymphocyte-rich population, and consisted of 76% lymphocytes, 23% macrophages, and 1% polymorphonuclear leucocytes (PMN). Adherent cells were harvested by cooling on ice for 1 h, for further use as the macrophage-rich population. Alveolar macrophages averaged 89% of the cell populations when determined by nonspecific esterase staining and light microscopic observations of Giemsa-stained preparations. Lymphocytes and PMN occupied 10 and 1% of the cell population, respectively.

Preparation of peripheral blood mononuclear cells and standard cells

Peripheral blood mononuclear cells (PBMC) were isolated from 10–20 ml of heparinized peripheral blood by Ficoll-Hypaque density gradient centrifugation, as described previously [24]. MT2 cells which contain HTLV-I proviral DNA [25] were serially diluted with HTLV-I-negative normal PBMC to make positive standard cells containing the following percentages of HTLV-I-infected cells: 0, 0.1, 1, 2.5, 5, 10, 25, 50 and 100%.

Identification of T-lymphocyte subsets

The T-lymphocytes and subsets in BAL fluid were identified by laser cytofluorography, using Ortho Spectrum III [20]. After gating on forward and right angle scatter, fluorescein isothiocyanate (FITC)-conjugated murine monoclonal antibodies (CD3, CD4, and CD8; Ortho Diagnostics, Raritan, NJ, USA) were used to identify specific subsets, as reported by PERSSON and EKLUND [26].

Extraction of high molecular weight DNA

After cell samples were lysed by means of sodium dodecyl sulphate/proteinase K digestion, chromosomal DNA was purified by means of phenol/chloroform extraction and ethanol precipitation. The DNA concentration of each sample was determined by measuring spectrophotometrically the absorbance ratio at 260/280 nm.

Amplification of HTLV-I DNA by PCR

A half microgram of total genomic DNA was used for PCR amplification with the primer pairs of the HTLV-I envelope (*env*) gene region (E1: #5662 - #5685; 5'-CTCCCTTCTAGTCGACGCTCCAGG-3'; E2: #6133 - #6110; 5'-GACCGCCACCGGTACCGCTCGGCG-3'), which give a 472-base pair (bp) fragment. The primer E1 and an internal primer (E3: #5897 - #5874; 5'-GGACGTGCCAAGTGGAGAGGCTGG-3'), which give a 236-bp fragment were used for the second PCR. The amplification was performed with 30 cycles of PCR, in 50 μ l aliquots, containing 0.5 μ g sample DNA, 10 pM of each primer, 200 μ M of d-adenosine triphosphate (dATP), d-cytosine triphosphate (dCTP), d-guanosine triphosphate (dGTP), and d-thymidine triphosphate (dTTP), 50 mM KCl, 10 mM Tris (pH 8.3), 1.0 mM MgCl₂, 0.1% Nonidet P-40, 0.02% gelatin and 1 unit of *Thermus aquaticus* (Taq) enzyme. Each cycle started with denaturation at 94°C for 1 min, followed by annealing at 57°C for 2 min, and extension at 72°C for 2 min. The reaction products were electrophoresed through a 1% agarose gel containing ethidium bromide, and photographed using positive/negative instant pack film (Polaroid Corp., MA, USA) for the densitometric determination of the HTLV-I DNA bands [27]. In each experiment, DNA extracted from diluted MT2 cells was used as the positive standard.

Results

Chest X-rays

All patients with HTLV-I uveitis were examined by routine chest X-rays, and no abnormalities were found, with the exception of one patient who had an inactive tuberculous lesion in the left upper lobe (case no. 3 in table 1). In the group with ocular sarcoidosis, four patients showed normal chest X-rays (stage 0) and another seven patients had bilateral hilar lymphadenopathy, with

(stage II: three patients), or without (stage I: four patients) pulmonary infiltrate. Asymptomatic HTLV-I carriers and normal control subjects showed normal chest X-rays.

Characteristics of BAL cells

BAL findings in five asymptomatic HTLV-I carriers were as follows: total cells $7 \pm 3 \times 10^4 \text{ ml}^{-1}$, differential cell counts: 85 \pm 8% alveolar macrophages, 13 \pm 7% lymphocytes, 2 \pm 1% polymorphonuclear leucocytes. These findings were similar to those of normal control subjects. However, in patients with HTLV-I uveitis, total cell counts were increased in 9 of 11 patients as shown in table 2. Two of these (cases no. 10 and 11) were current smokers and showed a high proportion of alveolar macrophages (89.3 and 93.0%, respectively). Two patients (cases no. 8 and 9) have been treated with oral prednisolone and showed normal differential cell counts. On the other hand, five patients (cases no. 1-5) showed higher proportion of lymphocytes (more than 20%), compared with normal control subjects. In case no. 6, the proportion of lymphocytes was not increased, but the number of lymphocytes was higher than that of normal control subjects. Thus, 6 out of 11 patients with HTLV-I uveitis had associated bronchoalveolar lymphocytosis (table 2).

The BAL lymphocytes increased in patients with HTLV-I uveitis were CD3+ T-cells, CD4+/CD8+ ratios were less than 1.0 in three patients (cases no. 1-3), and almost normal in other three patients (cases no. 4-6). Two patients without BAL lymphocytosis (cases no. 10 and 11) were current smokers, and showed decreased CD4+/CD8+ ratios. Patients with ocular sarcoidosis showed increased total cell counts ($26 \pm 11 \times 10^4 \text{ ml}^{-1}$) and BAL T-lymphocytosis (42 \pm 15%), with high CD4+/CD8+ ratios (6.3 \pm 3.8). In asymptomatic carriers, T-lymphocyte subsets were comparable to those of normal control subjects (table 3).

Table 2. - Bronchoalveolar findings in patients with HTLV-I uveitis

Case no.	Recovery ratio	Total cell counts $\times 10^4 \text{ ml}^{-1}$	Differential cell counts %				
			PAM	Lymph	PMN	Eos	
1	47	26.5	58.8	40.2 (10.7) [†]	0.8	0.2	
2	70	20.1	59.0	40.0 (8.0)	0.8	0.2	
3	71	13.5	69.8	26.7 (3.6)	1.5	2.0	
4	31	28.9	71.2	24.4 (7.1)	4.3	0.1	
5	70	19.6	77.5	20.9 (4.1)	1.3	0.3	
6	43	21.5	84.0	15.4 (3.3)	0.5	0.1	
7	43	5.7	97.0	2.5 (0.1)	0.4	0.1	
8 [#]	40	18.2	89.0	10.0 (1.8)	0.8	0.2	
9 [‡]	43	7.1	92.0	7.5 (0.5)	0.5	0.1	
10*	50	17.6	89.3	9.7 (1.7)	0.7	0.3	
11*	37	16.9	93.0	5.0 (0.8)	1.7	0.3	
Normal controls							
n=9	45 \pm 10	5.9 \pm 2.4	87.7 \pm 9.6	10.3 \pm 2.6 (0.6 \pm 0.2)	1.8 \pm 1.2	>0.2	

Individual values are given for HTLV-I uveitis patients, mean \pm SD for normal controls. *: current smokers; #: prednisolone 10 mg-day⁻¹; ‡: prednisolone 25 mg-day⁻¹. †: absolute number of lymphocytes is shown in parenthesis ($\times 10^4$ cells ml⁻¹). PAM: pulmonary alveolar macrophages; Lymph: lymphocytes; PMN: polymorphonuclear leucocytes; Eos: eosinophils. For further abbreviations see legend to table 1.

Quantitation of HTLV-I-infected cells

Amplification of HTLV-I DNA using the primer pairs (E1 and E2) of the *env* region, gave a 472-bp band on agarose gel electrophoresis, as expected. These PCR products were confirmed to be HTLV-I DNA fragments by means of the second PCR with the HTLV-I-specific internal primer pairs (E1 and E3), which gave a 236-bp

Table 3. - T-lymphocyte subsets in bronchoalveolar lavage fluid

Case no.	T-lymphocyte subsets			
	CD3+ %	CD4+ %	CD8+ %	CD4+/CD8+ ratio
HTLV-I uveitis				
1	95	38	61	0.6
2	87	34	58	0.6
3	91	28	64	0.4
4	77	42	40	1.1
5	87	62	33	1.9
6	88	54	33	1.6
7	92	61	37	1.7
8 ^a	77	57	29	2.0
9 ^b	70	47	31	1.5
10 [*]	62	20	59	0.3
11 [*]	92	35	60	0.6
Asymptomatic carriers[†]				
(n=5)	77±4	56±6	28±5	2.1±0.4
Sarcoidosis with uveitis[†]				
(n=11)	79±6	68±7	15±6	6.3±3.8
Normal control subjects[†]				
(n=9)	71±7	42±6	35±9	1.2±0.4

*: current smokers; ^a: prednisolone 10 mg·day⁻¹; ^b: prednisolone 25 mg·day⁻¹; [†]: values are mean±SD. Total cell counts and the proportion of lymphocytes were 26±11×10⁶·ml⁻¹ and 42±15% respectively, in sarcoidosis patients with uveitis, and 7±3×10⁶·ml⁻¹ and 13±7% respectively, in asymptomatic carriers.

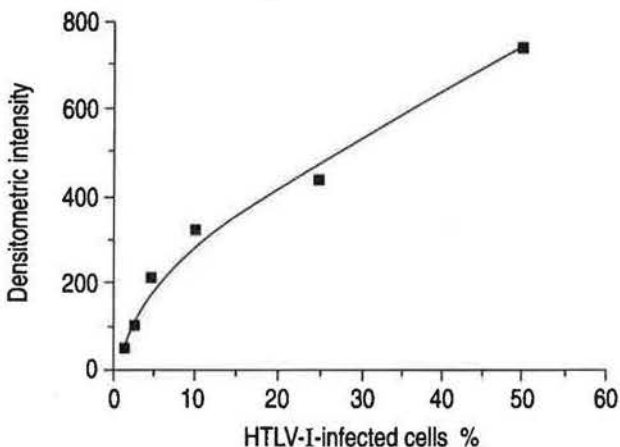


Fig. 1. - Densitometric measurement of the amplified HTLV-I DNA fragments. Shown is the standard curve which was prepared for each experiment to estimate the intensity of HTLV-I DNA bands. The abscissa indicates the percentage of MT2 cells and the ordinate indicates densitometric intensity of the bands (arbitrary units). HTLV-I: human T-cell lymphotropic virus type-1; DNA: deoxyribonucleic acid.

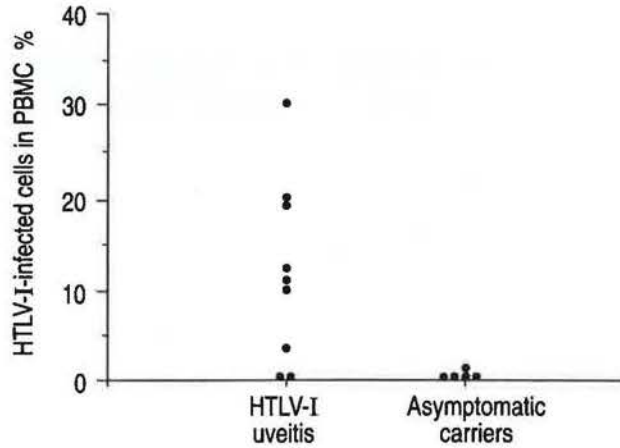


Fig. 2. - The proportion of HTLV-I-infected cells in the PBMC obtained from patients with HTLV-I uveitis and asymptomatic HTLV-I carriers. HTLV-I: human T-cell lymphotropic virus type-1; PBMC: peripheral blood mononuclear cells.

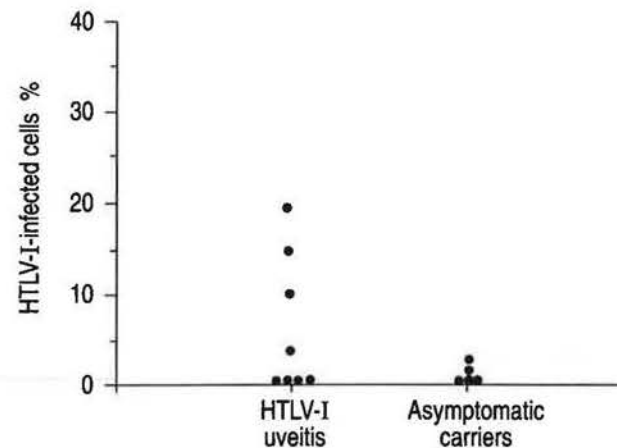


Fig. 3. - The proportion of HTLV-I-infected cells in the BALF obtained from patients with HTLV-I uveitis and asymptomatic HTLV-I carriers. HTLV-I: human T-cell lymphotropic virus type-1; BALF: bronchoalveolar lavage fluid.

band, and also by means of Southern blot analysis using HTLV-I DNA probe (data not shown). The intensity of signals from HTLV-I DNA fragments amplified by PCR correlated well with the proportion of HTLV-I-infected cells, when standard DNA from the MT2 cells was used as the positive control. The representative standard curve is shown in figure 1. Using this quantitative PCR, HTLV-I-infected cells were estimated to be present in 1-30% (12±9%) of the PBMC obtained from nine patients with HTLV-I uveitis. As shown in figure 2, these values were much higher than those in asymptomatic HTLV-I carriers (0.1-1% of the PBMC). The proportion of HTLV-I infected cells in BAL fluid was determined in eight patients with HTLV-I uveitis. As shown in figure 3, HTLV-I infected cells were present in less than 1% of BAL cells in four patients without BAL lymphocytosis. However, four other patients with BAL lymphocytosis showed that HTLV-I-infected cells were present in 4-18% (12±5%) of BAL cells. Three of these patients showed a higher percentage of HTLV-I-infected cells in BAL fluid than that found in PBMC (fig. 4). In these three




Fig. 4. — The DNA fragment amplified by PCR using the primer pairs of *env* region of HTLV-I proviral DNA. Lane 1: standard HTLV-I DNA (50%), lanes 2 and 3: BAL cells and PBMC respectively, obtained from a patient without pulmonary involvement. Lanes 4 and 5: BAL cells and PBMC, respectively, from one patient with pulmonary involvement. Lanes 6 and 7: BAL cells and PBMC, respectively, from another patient with pulmonary involvement. PCR: polymerase chain reaction; DNA: deoxyribonucleic acid; bp: base pair. For further abbreviations see legends to figures 2 and 3.

patients, the proportion of HTLV-I-infected cells was less than 2% in the alveolar macrophage-rich population and 10–40% in the lymphocyte-rich population. HTLV-I-infected cells in BAL fluid were not increased in asymptomatic HTLV-I carriers.

Discussion

The present study showed that there was bronchoalveolar T-lymphocytosis in patients with HTLV-I uveitis. A frequent association of T-lymphocyte alveolitis with HAM/TSP has been reported by COUDERC *et al.* [18] and by SUGIMOTO and co-workers [19, 20]. However, bronchoalveolar T-lymphocytosis has not previously been reported in patients with HTLV-I uveitis and without HAM/TSP. Thus, this report is the first to describe pulmonary involvement in patients with HTLV-I uveitis. Although pulmonary involvement is not so frequent in HTLV-I uveitis compared to HAM/TSP, the present study provides further evidence of the HTLV-I tropism for the lung. It is well-known that patients with adult T-cell leukaemia and lymphoma (ATL), another condition induced by HTLV-I, often show the pulmonary complications due to opportunistic infections or leukaemic cell infiltration [21]. In patients with HTLV-I uveitis, however, leukaemic cells or pathogens of opportunistic infections, such as *Pneumocystis carinii*, cytomegalovirus, fungi, or tubercle bacilli were not found. Hence, the pathogenesis of pulmonary involvement in patients with HTLV-I uveitis is probably different from that in patients with ATL.

Ocular manifestation in HTLV-I uveitis is mostly due to an intermediate type of uveitis characterized by the opacity of vitreous body, iritis, and retinal vasculitis with mononuclear cell infiltration [15]. These pathological findings raise the possibility that similar mechanisms may play a role in the development of uveitis and lymphocyte alveolitis. Ocular findings of HTLV-I uveitis have some similarities to those of ocular sarcoidosis. However, the phenotypic evaluation of BAL cells clearly showed that there was a large difference in the lymphocytic component between HTLV-I uveitis and sarcoidosis. These observations may be important, not only in understanding the pathogenesis of HTLV-I uveitis, but also in discriminating HTLV-I uveitis from a concomitant association of ocular sarcoidosis and HTLV-I infection. HTLV-I-positive patients with sarcoidosis are occasionally found in endemic areas of HTLV-I infection.

The report by COUDERC *et al.* [18] suggested that cytotoxic immune responses by CD8+ T-cells were responsible for the development of T-lymphocyte alveolitis in HAM/TSP. Since BAL findings in patients with HTLV-I uveitis resemble those of patients with HAM/TSP, such immunological mechanisms may also play a role in the pathogenesis of pulmonary involvement in HTLV-I uveitis. On the other hand, we have shown that both CD4+ and CD8+ cells equally account for the increased number of lymphocytes in BAL fluid recovered from Japanese patients with HAM/TSP [20]. These observations suggest that other mechanisms are also considered for the expansion of T-lymphocytes in the lower respiratory tract of patients with HTLV-I uveitis.

Using Southern blots, GESSAIN *et al.* [28] showed that HTLV-I proviral DNA was present in 3–15% of the PBMC from patients with HAM/TSP [28]. Using quantitative PCR, and hypothesizing that a single copy of HTLV-I proviral DNA was present in haploid genome, we estimated that 3–30% of the PBMC were infected by HTLV-I in Japanese patients with HAM/TSP [22, 27]. The data obtained by the quantitative PCR are comparable with those of GESSAIN *et al.* [28], despite differences in assay methods. Using this PCR technique, we obtained evidence for a large number of HTLV-I-infected cells in the PBMC of patients with HTLV-I uveitis, compared to the findings in asymptomatic HTLV-I carriers. Interestingly, the proportion of HTLV-I-infected cells was also increased in BAL fluid of patients with bronchoalveolar T-lymphocytosis, and was higher in BAL fluid than in the PBMC of these patients. HTLV-I has a peculiar tropism for T-lymphocytes, and the cells infected by this virus were present mostly in the lymphocyte-rich population of BAL fluid. DESGRANGES and co-workers [29] showed that HTLV-I proviral DNA was present in alveolar lymphocytes, but not in adherent cells of BAL fluid. Thus, we suspect that T-lymphocytes in BAL fluid are the main cells infected by HTLV-I proviral DNA. However, it may be possible that other cells in the lung such as B-cells, fibroblasts, or epithelial cells are infected by this virus.

In HTLV-I-infected T-lymphocytes, a partial activation of interleukin-2 (IL-2) and IL-2 receptor gene expression occurs through the action of the viral pX gene product (Tax) [30, 31], probably leading to spontaneous proliferation of T-lymphocytes through autocrine or paracrine pathways [24]. Using reverse transcriptase RT-PCR and *in situ* hybridization technique, we showed the expression of HTLV-I pX gene in fresh uncultured BAL cells from patients with HAM/TSP [22]. These observations suggest that HTLV-I-infected cells in the lung play a central role for expansion of bronchoalveolar T-lymphocytes in patients with HTLV-I uveitis. Such mechanisms may also be responsible for the development of HTLV-I uveitis, because HTLV-I-infected cells have been demonstrated in the aqueous humour of patients with HTLV-I uveitis [13, 32]. For this issue, HTLV-I expression in the cells of aqueous humour or ocular tissues remains to be investigated. Based on the data presented here, it seems reasonable to conclude that a local and systemic increase of HTLV-I proviral DNA load plays an impor-

tant role in the pathogenesis of T-lymphocyte alveolitis occurring in patients with HTLV-I uveitis.

References

- Roman GC. - The neuroepidemiology of tropical spastic paraparesis. *Ann Neurol* 1988; 23 (Suppl.): 113-120.
- Gessain A, Barin F, Vernant JC, et al. - Antibodies to human T-lymphotropic virus type-I in patients with tropical spastic paraparesis. *Lancet* 1985; ii: 407-410.
- Vernant JC, Maurs L, Gessain A, et al. - Endemic spastic paraparesis associated with human T-lymphotropic virus type-I: a clinical and seroepidemiological study of 25 cases. *Ann Neurol* 1987; 21: 123-130.
- Osame M, Usuku K, Izumo, et al. - HTLV-I-associated myelopathy, a new clinical entity. *Lancet* 1987; i: 1031-1032.
- Osame M, Matsumoto M, Usuku K, et al. - Chronic progressive myelopathy associated with elevated antibodies to human T-lymphotropic virus type-I and adult T-cell leukemia like cells. *Ann Neurol* 1987; 21: 117-122.
- Bhagavati S, Ehrlich G, Kula RW, et al. - Detection of human T-cell lymphoma/leukemia virus type-I DNA and antigen in spinal fluid and blood of patients with chronic progressive myelopathy. *N Engl J Med* 1988; 318: 1141-1147.
- Gessain A, Gout O, Caudie C, et al. - Chronic progressive myelopathies associated with HTLV-I in French West Indies, Africa and France: a clinical, serological, and immunovirological update. In: Roman GC, Vernant JC, Osame M, eds. HTLV-I and the nervous system. New York, Alan R. Liss, 1989; pp. 103-122.
- Cruickshank JK, Rudge P, Dalglish AG, et al. - Tropical spastic paraparesis and human T-cell lymphotropic virus type-I in the United Kingdom. *Brain* 1989; 112: 1057-1090.
- Poiesz BJ, Ruscetti FW, Gazdar AF, et al. - Detection and isolation of type C retrovirus particles from fresh and cultured lymphocytes of patients with cutaneous T-cell lymphoma. *Proc Natl Acad Sci USA* 1980; 77: 7415-7419.
- Hinuma Y, Nagata K, Hanaoka M, et al. - Adult T-cell leukemia: antigen in an ATL cell line and detection of antibodies to the antigen in human sera. *Proc Natl Acad Sci USA* 1981; 78: 6476-6480.
- Roman GC, Osame M. - Identity of HTLV-I-associated spastic paraparesis and HTLV-I-associated myelopathy. *Lancet* 1988; i: 651.
- Nussenblatt RB, Palestine AG. - In: Uveitis fundamentals and clinical practice. Chicago, Year Book Medical Publishers, 1989; pp. 163-430.
- Mochizuki M, Watanabe T, Yamaguchi K, et al. - HTLV-I uveitis: a distinct clinical entity caused by HTLV-I. *Jpn J Cancer Res* 1992; 83: 236-239.
- Mochizuki M, Watanabe T, Yamaguchi K, et al. - Uveitis associated with human T-cell lymphotropic virus type-I (HTLV-I): seroepidemiological, clinical and virological studies. *J Infect Dis* 1992; 166: 943-944.
- Mochizuki M, Watanabe T, Yamaguchi K, et al. - Uveitis associated with human T-cell lymphotropic virus type-I. *Am J Ophthalmol* 1992; 114: 123-129.
- Ohba N, Matsumoto M, Sameshima M, et al. - Ocular manifestations in patients with human T-lymphotropic virus type-I. *Jpn J Ophthalmol* 1989; 33: 1-12.
- Nakao K, Matsumoto M, Ohba N. - Seroprevalence of antibodies to HTLV-I in patients with ocular disorders. *Br J Ophthalmol* 1991; 75: 76-78.
- Couderc LJ, Caubarrere I, Venet A, et al. - Bronchoalveolar lymphocytosis in patients with tropical spastic paraparesis associated with human T-cell lymphotropic virus type-I (HTLV-I): clinical, immunologic, and cytologic studies. *Ann Intern Med* 1988; 109: 625-628.
- Sugimoto M, Nakashima H, Watanabe S, et al. - T-lymphocyte alveolitis in HTLV-I-associated myelopathy. *Lancet* 1987; ii: 1220.
- Sugimoto M, Nakashima H, Matsumoto M, et al. - Pulmonary involvement in patients with HTLV-I-associated myelopathy: increased soluble IL-2 receptors in bronchoalveolar lavage fluid. *Am Rev Respir Dis* 1989; 139: 1329-1335.
- Yoshioka R, Yamaguchi K, Yoshinaga T, Takatsuki K. - Pulmonary complications in patients with adult T-cell leukemia. *Cancer* 1985; 55: 2491-2494.
- Sugimoto M, Mita S, Tokunaga M, et al. - T-cell alveolitis associated with HTLV-I infection: increased HTLV-I-infected cells in bronchoalveolar lavage fluid. *Am Rev Respir Dis* 1992; 145 (Suppl.): A751.
- Ikeda M, Fujino R, Matsui T, et al. - A new agglutination test for serum antibodies to adult T-cell leukemia virus. *Gann* 1984; 75: 845-848.
- Matsumoto M, Sugimoto M, Nakashima H, et al. - Spontaneous T-cell proliferation and release of soluble interleukin-2 receptors in patients with HTLV-I-associated myelopathy. *Am J Trop Med Hyg* 1990; 42: 365-373.
- Kobayashi N, Konishi H, Sabe H, et al. - Genomic structure of HTLV (human T-cell leukemia virus): detection of defective genome and its amplification in MT2 cells. *Embo J* 1984; 3: 1339-1343.
- Persson U, Eklund A. - Alveolar lymphocytes from patients with sarcoidosis respond poorly to activation by mitogenic lectins. *Int Arch Allergy Appl Immunol* 1986; 80: 185-191.
- Mita S, Sugimoto M, Nakamura M, et al. - Increased HTLV-I proviral DNA in peripheral blood mononuclear cells and bronchoalveolar lavage cells in Japanese patients with HTLV-I-associated myelopathy. *Am J Trop Med Hyg*, 1993; 48: 170-177.
- Gessain A, Saal F, Gout O, et al. - High human T-cell lymphotropic virus type-I proviral DNA load with polyclonal integration in peripheral blood mononuclear cells of French West Indian, Guianese, and African patients with tropical spastic paraparesis. *Blood* 1990; 75: 428-433.
- Desgranges C, Bechet JM, Couderc LT, Caubarrere I, Vernant JC. - Detection of HTLV-I DNA by polymerase chain reaction in alveolar lymphocytes of patients with tropical spastic paraparesis. *J Infect Dis* 1989; 160: 162-163.
- Leung K, Nabel GJ. - HTLV-I transactivator induces interleukin-2 receptor expression through an NF-kappa B-like factor. *Nature* 1988; 333: 776-778.
- Tendler CL, Greenberg SJ, Blattner WA, et al. - Transactivation of interleukin-2 and its receptor induces immune activation in human T-cell lymphotropic virus type-I-associated myelopathy: pathogenic implications and a rationale for immunotherapy. *Proc Natl Acad Sci USA* 1990; 87: 5218-5222.
- Mochizuki M, Yamaguchi K, Takatsuki K, et al. - HTLV-I and uveitis. *Lancet* 1992; 339: 1110.