

CASE REPORT

Pulmonary veno-occlusive disease and Hodgkin's lymphoma

G.L. Swift*, A. Gibbs*, I.A. Campbell*, C.A. Wagenvoort**, D. Tuthill*

Pulmonary veno-occlusive disease and Hodgkin's lymphoma. G.L. Swift, A. Gibbs, I.A. Campbell, C.A. Wagenvoort, D. Tuthill.

ABSTRACT: Pulmonary veno-occlusive disease (PVOD) is a rare cause of pulmonary hypertension, and is of unknown aetiology. It has seldom been described in association with malignant disease and cytotoxic chemotherapy, and there have been only two previous reports of an association with Hodgkin's disease [1, 2]. We report a third case which developed 14 yrs after Hodgkin's disease had been diagnosed and treated, initially with radiotherapy and subsequently with chemotherapy. *Eur Respir J.*, 1993, 6, 596-598.

* Depts of Chest Medicine and Pathology, Llandough Hospital, Cardiff, UK. ** Dept of Pathology, Erasmus University, Rotterdam, The Netherlands.

Correspondence: A. Gibbs
Dept of Chest Medicine and Pathology
Llandough Hospital
Cardiff CF6 1XX, UK.

Keywords: Chemotherapy
Hodgkin's lymphoma
pulmonary veno-occlusive disease

Received: June 23 1992

Accepted after revision January 1 1993

We present a rare case of pulmonary veno-occlusive disease following treatment of Hodgkin's disease; there have been only 2 previous reports of this association [1, 2].

Case report

A 34 yr old man presented with dyspnoea on exertion, which had developed rapidly over a few days. Fourteen years previously he had been treated for stage 1A nodular sclerotic Hodgkin's disease by means of inverted Y radiotherapy (40 Gy in 20 fractions, over 28 days). He remained in remission for 8 yrs, but then developed lymphadenopathy in the left supraclavicular fossa; a biopsy showed recurrent disease. He received cyclophosphamide, prednisolone and localized radiotherapy. For the next 6 yrs he remained asymptomatic and continued in full-time employment. At the onset of his breathlessness, physical examination was normal, as were routine blood tests and pulmonary function tests. Chest X-ray showed bilateral basal infiltrate and computed tomographic (CT) scan of the thorax showed nonspecific interstitial shadowing.

Symptoms increased gradually over the following six months, and repeat chest X-rays and CT scans showed increased interstitial shadowing. Recurrent Hodgkin's disease was presumed, and the patient was given two courses of mustine, oncovin (vincristine), procarbazine and prednisolone (MOPP). In the subsequent two months, he felt weak, lost his appetite and became dyspnoeic at rest. Coagulation screen was normal but plasma viscosity was raised to 2.09 mps. (normal range 1.5-1.72). The bilateral pulmonary infiltrate worsened (figs 1 and 2), and he became hypoxaemic, with arterial oxygen tension (Pao₂) of 43 mmHg (5.7 kPa) and arterial carbon dioxide tension of 27 mmHg (3.6 kPa) breathing air.

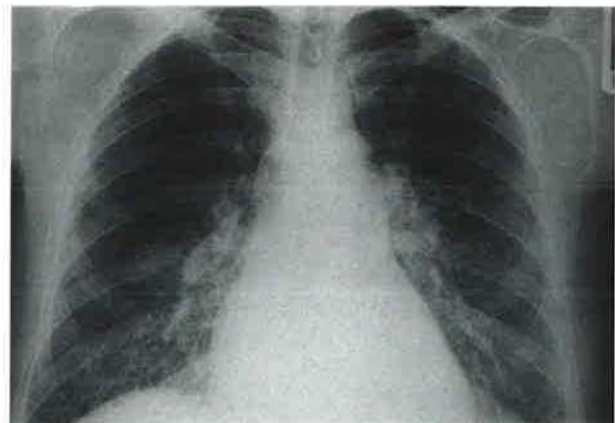


Fig. 1. - The chest X-ray shows reticulonodular shadowing in the lower zones and septal lines seen most clearly at the right base. There are prominent pulmonary vessels.

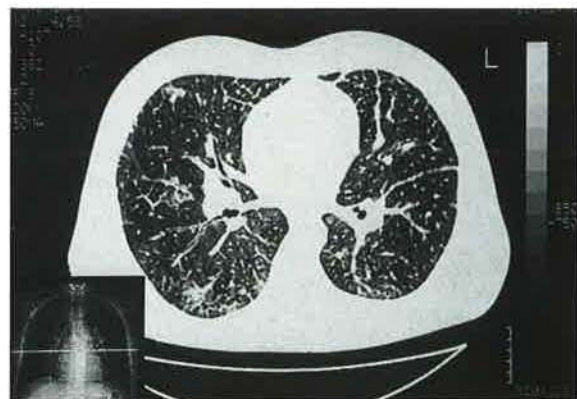


Fig. 2. - A slice of the computed tomographic (CT) scan shows thickened interlobular septae, mainly subpleurally, but also extending centrally. The left main fissure also appears thickened.

Bronchoscopy reportedly showed "the entire bronchial tree to be swimming in a pool of blood"; bronchial washings and biopsies were negative for malignant cells. Transbronchial biopsy was not considered possible, because of dyspnoea, and the patient was referred to Cardiff for open lung biopsy. However, the thoracic surgeons felt that he would not survive such a procedure. He developed signs on electrocardiogram (ECG) and echocardiogram of pulmonary hypertension with a mean pulmonary artery pressure of 55 mmHg. Two weeks later, his condition deteriorated rapidly; a diagnosis of possible pulmonary embolus was made on clinical grounds only, as he was too unwell for transfer for ventilation/perfusion scan or angiography to be performed. Anticoagulation was commenced with heparin, but the patient died within 24 h in cardiorespiratory failure, 13 months after initial presentation.

At postmortem the major changes were found in the cardiovascular and respiratory systems. The heart weighed 520 g, and showed severe biventricular hypertrophy, but no congenital abnormalities. The lungs were heavy (the left 1,100 g, and the right 1,200 g), firm and mottled reddish brown throughout. There were numerous bilateral pleural adhesions. The liver showed marked centrilobular congestion. No evidence of recurrent tumour was found.

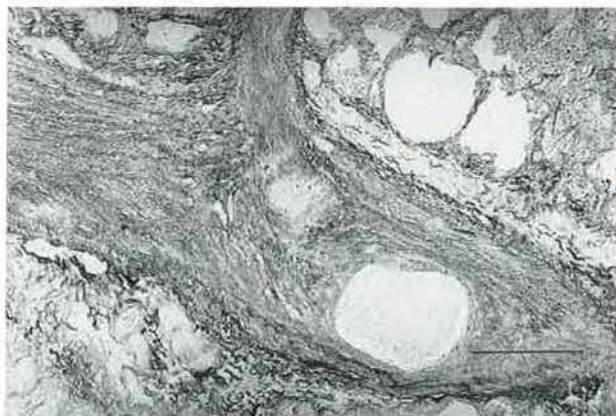

Fig. 3. - A pulmonary vein showing partial occlusion by marked intimal fibrosis (scale bar 100 μ m).

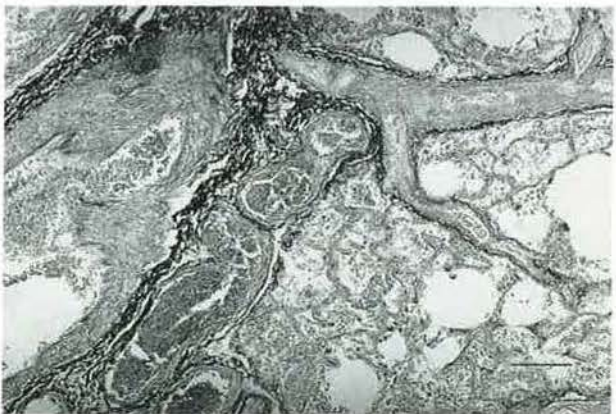


Fig. 4. - Pulmonary veins showing intimal fibrosis and clusters of dilated veins (or venous anastomoses with bronchial veins). There is marked interstitial fibrosis (scale bar 100 μ m).

Microscopically the lungs showed areas of haemorrhage, and haemosiderosis, and areas of mild interstitial fibrosis. The pulmonary veins showed severe abnormalities; many were occluded by loose fibrous tissue within the intima, others by recanalized organized tissue (fig. 3). There were also striking networks of wide thin-walled veins around bronchi and vessels, which were in part pulmonary veins, in part bronchial veins and in part venous anastomoses (fig. 4). There was prominent medial hypertrophy of the pulmonary arteries, but significant intimal fibrosis and dilatation lesions were absent. The appearances were considered to be those of pulmonary veno-occlusive disease.

Discussion

Pulmonary veno-occlusive disease (PVOD) is a rare cause of pulmonary hypertension. Diagnosis is often difficult, and is usually only made after open lung biopsy or at autopsy, but may be suspected when signs of severe pulmonary hypertension are accompanied by evidence of pulmonary oedema or effusions. Cardiac catheterization reveals high pulmonary artery pressure, but normal left atrial pressure. Pulmonary arterial angiography shows regions of poor perfusion where thromboses are present. Morphologically PVOD is characterized by occlusion of large numbers of veins by organized thrombus, fibrosis, and some recanalization, together with many engorged hyperplastic lymphatics and haemosiderosis. Arteries may also show similar occlusions [3]. The aetiology is unknown, but may be multifactorial. One case has been reported in association with autoimmune vasculitis [4], and some have been reported after viral or toxoplasma infections [5]. Chemotherapy agents, and possibly malignant disease *per se*, have also been implicated, but because of the dearth of literature on the subject the association between PVOD and malignancy is unclear. LOMBARD *et al.* [2] reviewed nine patients with PVOD after treatment of malignant disease with a variety of cytotoxic chemotherapy. The interval between treatment and onset of symptoms ranged from 1.5 months to 10 yrs, with survival times between one week and 12 months. One was a patient with Hodgkin's lymphoma treated with courses of chemotherapy, including cyclophosphamide, and radiotherapy 10 yrs prior to the onset of dyspnoea. After such a long latent period, the association between treatment and PVOD may be considered doubtful. However, cyclophosphamide-induced pulmonary fibrosis has been described up to 13 yrs after chemotherapy [6]. PVOD thought to be associated with Hodgkin's disease *per se* has been described once [1]. This patient had evidence of severe pulmonary hypertension and grossly disturbed pulmonary perfusion suggestive of multiple emboli prior to two courses of MOPP. PVOD was confirmed histologically after open lung biopsy.

The possible cause of PVOD in our patient is unclear, but includes chemotherapeutic agents, Hodgkin's disease and radiotherapy. On clinical grounds it can be assumed that PVOD preceded his MOPP therapy. Although radiation has been reported to cause hepatic veno-occlusive disease [7], there is little evidence to suggest that radiation plays a significant role in the development of PVOD

[2, 8]; most radiation-induced pulmonary damage occurs in the first year following therapy [9] and only in the field of irradiation. It is, therefore, unlikely to be of relevance in our patient.

In this man, we believe that PVOD was associated with the Hodgkin's disease *per se* and, if so, it appears to be a late and rare complication. There is no evidence that the occlusive lesions respond to any currently available therapy and, thus, earlier diagnosis would not have altered the outcome.

References

1. Capewell SJ, Wright AJ, Ellis DA. - Pulmonary veno-occlusive disease in association with Hodgkin's disease. *Thorax* 1984; 39: 554-555.
2. Lombard CM, Churg A, Winokur S. - Pulmonary veno-occlusive disease following therapy for malignant neoplasms. *Chest* 1987; 92: 871-876.
3. Wagenvoort CA, Wagenvoort N, Takahashi T. - Pulmonary veno-occlusive disease: involvement of pulmonary arteries and review of the literature. *Hum Pathol* 1985; 16: 1033-1041.
4. Sanderson JE, Spiro SG, Hendry AT, Turner-Warwick M. - A case of pulmonary veno-occlusive disease responding to treatment with azathioprine. *Thorax* 1977; 32: 140-148.
5. Anonymous. - Pulmonary veno-occlusive disease. *Br Med J* 1972; ii: 369.
6. Cooper JAD, White DA, Matthey RA. - Drug-induced pulmonary disease. *Am Rev Respir Dis* 1986; 133: 321-340.
7. Fajardo LF, Colby TV. - Pathogenesis of veno-occlusive liver disease after radiation. *Arch Pathol Lab Med* 1980; 104: 585-588.
8. Daroca PJ, Mansfield RE, Ichinose H. - Pulmonary veno-occlusive disease: report of a case with pseudo-angiomatous features. *Am J Surg Pathol* 1977; 1: 349-355.
9. Gross NJ. - Pulmonary effects of radiation therapy. *Ann Intern Med* 1977; 86: 81-92.