Pulmonary manifestations of human herpesvirus-8 during HIV infection

Raphael Borie[1], Jacques Cadranel[2,3], Amélie Guihot[4,5], Anne Geneviève Marcelin[6,7], Lionel Galicier[8] and Louis-Jean Couderc[9,10,11]

Affiliations: [1]Service de Pneumologie A, Centre de Compétence Maladies Pulmonaires Rares, Hôpital Bichat, APHP, Paris, [2]Service de Pneumologie, Centre de Compétence Maladies Pulmonaires Rares, Hôpital Tenon, APHP, Paris, [3]Faculté de Médecine Pierre et Marie Curie, Université Paris VI, Paris, [4]Université Pierre et Marie Curie – Paris 6, APHP, Hôpital Pitié Salpêtrière, Paris, [5]Département d'Immunologie, INSERM, UMR S945, Paris, [6]Service de Virologie, Hôpital Pitié-Salpêtrière, APHP, Paris, [7]INSERM, UMR S943, Université Pierre et Marie Curie, Paris, [8]Service d'Immunopathologie Clinique, Hôpital Saint Louis, APHP, Paris, [9]Service de Pneumologie, Hôpital Foch, Suresnes, [10]Faculté de Médecine Paris Ile de France Ouest, Guyancourt, and [11]Université Versailles Saint Quentin en Yvelines, Versailles, France.

Correspondence: R. Borie, Service de Pneumologie A, Hôpital Bichat, 46 rue Henri Huchard, 75877 Paris, CEDEX 18, France. E-mail: raphael.borie@bch.aphp.fr

ABSTRACT Human herpesvirus (HHV)-8 is an oncogenic gamma herpesvirus that was first described in 1994 in Kaposi sarcoma lesions. HHV-8 is involved in the pathophysiological features of multicentric Castleman's disease (MCD) and primary effusion lymphoma (PEL), both rare B-cell lymphoproliferative diseases. HHV-8-related tumours occur almost exclusively in immunocompromised patients, mostly those with HIV infection. Combined antiretroviral therapies have reduced the incidence of Kaposi sarcoma but not MCD and PEL.

HHV-8-related diseases frequently exhibit pulmonary involvement, which may indicate the disease. Kaposi sarcoma in the lung is often asymptomatic but may require specific therapy. It mostly shows cutaneous or mucosal involvement. Patients with typical MCD present fever and lymphadenopathy associated with interstitial lung disease without opportunistic infection. Specific treatment may be urgent. PEL provokes a febrile, lymphocytic-exudative pleural effusion, without a pleural mass on computed tomography scan. Rapid diagnosis prevents unnecessary examinations and leads to specific, rapid treatment. Therapy is complex, combining antiretroviral therapy and chemotherapy.

@ERSpublications
HHV-8-related diseases frequently exhibit pulmonary involvement, which may indicate the disease
http://ow.ly/ngJ65

Received: Sept 28 2012 | Accepted after revision: Nov 27 2012 | First published online: Feb 08 2013

Conflict of interest: None declared.

Copyright ©ERS 2013

Introduction

Human herpesvirus (HHV)-8, or Kaposi sarcoma herpesvirus, is the eighth and most recently discovered member of the HHVs. It was discovered in 1994 in Kaposi sarcoma lesions [1]. HHV-8 was later linked to multicentric Castleman's disease (MCD) and primary effusion lymphoma (PEL) [2–4]. Pulmonary manifestations of HHV-8 infection occur almost exclusively in immunocompromised patients, mostly during HIV infection. HHV-8 was suspected of being involved in the pathogenesis of pulmonary hypertension, sarcoidosis or multiple myeloma, without confirmation [5–7].

This narrative review briefly introduces the features of HHV-8, and then focuses on the clinical manifestations of HHV-8 infection and pulmonary manifestations of Kaposi sarcoma, MCD and PEL, mainly during HIV infection. This review involved a search of the literature on HHV-8 and the lung. We searched Medline *via* PubMed with the terms "HHV-8", "Castleman's disease", "Kaposi" and "primary effusion lymphoma" for articles published in English up to June 2012. We hand-searched the reference lists of clinically relevant articles for other articles. Titles were screened and then abstracts were read to select relevant articles. Abstracts describing studies of localised Castleman's disease, for example, were not read.

Human herpesvirus-8

Like all herpesviruses, HHV-8 is a double-stranded DNA virus. HHV-8 belongs to the γ2-herpesvirus, or *Rhadinovirus*. Genotypically, it is the closest HHV to oncogenic Epstein–Barr virus (EBV) (fig. 1) [9].

Like all herpesviruses, HHV-8 has two modes of viral replication: a lytic and a latent phase. In the latent phase, only a few viral genes are expressed in infected cells and the virus genome replicates with cellular mitosis. PCR revealed that during this phase, HHV-8 persists without detectable replication in the blood [10]. During the lytic phase, numerous genes are expressed and viral homologues of human pro-inflammatory cytokines, such as viral interleukin 6 (vIL-6), lead to inflammation, angiogenesis and cell growth. Most of the clinical effects of MCD are secondary to viral proteins such as vIL-6 [11–13].

The reservoir of HHV-8 is strictly human. It is endemic and persists in the latent phase in Africa and around the Mediterranean. The prevalence is almost 50% in sub-Saharan Africa, 30% in Sicily, and <1% in Northern Europe and Asia [14].

Primary HHV-8 infection is asymptomatic or results in non-specific signs of infection and is rarely diagnosed. A retrospective diagnosis of HHV-8 primary infection was reported: the patient presented fever, arthralgia and polyadenopathy, which may be mistaken for numerous viral primary infections [15].

In low-prevalence countries, HHV-8 transmission is mostly sexual, essentially in populations with high-risk sexual behaviour, with a high frequency of HIV and HHV-8 co-infection [14, 16]. HHV-8 may be transmitted by blood transfusion or organ transplantation [17, 18]. In high-prevalence countries, the seroprevalence increases during childhood, which suggests transmission between the mother and child, or sibling or playmate. Saliva may be the biological fluid implicated in both sexual and familial transmissions because it can contain high levels of HHV-8 [19, 20].

To evaluate its prevalence in epidemiological studies, HHV-8 infection is diagnosed by immunoglobulin (Ig)G-positive serology results [15]. The results of past studies were affected by the high variability of the available tests [21]. The sensitivity and specificity of current HHV-8 serology tests are 89–98% and 83–97%,

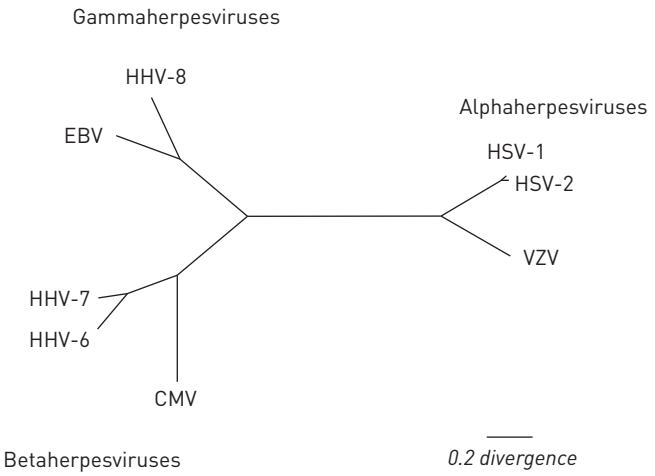

FIGURE 1 Phylogenetic tree of human herpesviruses (HHVs). EBV: Epstein–Barr virus; HSV: herpes simplex virus; VZV: varicella zoster virus; CMV: cytomegalovirus. Data adapted from [8].

DOI: 10.1183/09031936.00154212

TABLE 1 Diagnosis of human herpesvirus (HHV)-8 diseases associated with HIV infection

Disease	HHV-8 serology	PCR HHV-8	Co-infection with EBV	Histology and LANA staining
Kaposi sarcoma	Not required	<2 log	No	Not required
Multicentric Castleman's disease	Not required	2–4 log	No	Required
Primary effusion lymphoma	Not required	>4 log gradient between serum and pleural	70% of cases PCR or EBER hybridisation	Cytology required

EBV: Epstein–Barr virus; LANA: latency-associated nuclear antigen; EBER: EBV-encoded RNA.

respectively [22, 23]. This poor accuracy explains why serology is not used in clinical practice, and why HHV-8 infection is diagnosed by clinical examination, histology or PCR (table 1). Cells infected with HHV-8 may be identified by immunohistochemistry, because they express latency-associated nuclear antigen (LANA). Real-time PCR provides a quantitative approach to analyse HHV-8 viral load and results are correlated with the number of infected cells and type of disease [10, 24].

HHV-8 is an oncogenic virus infecting mostly B-cells in the latent state. However, in Kaposi sarcoma, the infected cells are spindle cells expressing some markers of endothelial cells [25]; in MCD they are naïve monotypic B-cells [26]; and in PEL, they are post-germinal B-cells [27]. Proliferation of infected spindle cells is lower than that of infected tumoural B-cells. The PCR-assessed viral load of HHV-8 is higher in PEL than Kaposi sarcoma. Indeed, blood viral load may be <2 log copies per 10^5 peripheral blood mononuclear cells (PBMCs) in Kaposi sarcoma, 2–4 log copies per 10^5 PBMCs in MCD and >4 log copies per 10^5 PBMCs in PEL [28]. However, PCR alone cannot be used for the diagnosis, and PCR results must be interpreted with clinical and histological data (table 1). Moreover, PCR results are often negative for patients with disease in remission or for asymptomatic HHV-8 carriers [10, 29].

HHV-8 diseases may appear in older patients with the classical Mediterranean Kaposi sarcoma form and MCD, or occasionally during immunosuppressive therapy. However, they are most frequently observed during HIV infection [30, 31].

Kaposi sarcoma

Epidemiology

Cutaneous Kaposi sarcoma was described 150 years ago in the Mediterranean area and in males in Middle Eastern countries [32]. Kaposi sarcoma was found frequently during HIV infection at the stage of AIDS. Moreover, in the 1980s, Kaposi sarcoma was one of the opportunistic infections leading to the description of AIDS and is an AIDS indicator. Combined antiretroviral therapy (cART) has been widely used since the middle of the 1990s, and the prevalence of Kaposi sarcoma has decreased from 30 per 1000 to 0.03 per 1000 patient-years [33]. Today, Kaposi sarcoma mainly occurs in patients without cART or with disease uncontrolled by cART, but can also be seen in cART-treated patients with low viraemia. The median CD4 cell count is about 150 cells·mm^{-3} [34]. Kaposi sarcoma during HIV infection can also appear at the beginning of cART. Indeed, several series of immune reconstitution syndrome associated with Kaposi sarcoma have been reported [35].

Clinical presentation

Cutaneous Kaposi sarcoma lesions are macules, papules or nodules that may evolve into ulcerative or indurate tumours. They are well delimited and red or purple (fig. 2). Lesions are painless and not pruritic. They may vary from a few millimetres to >10 cm in diameter. Chronic lesions may be associated with lymphatic oedema, known as Kaposi sarcoma-associated elephantiasis [36]. Lesions may be diffuse or localised, particularly to the trunk. Repartition may vary by type of immunodeficiency. Mediterranean Kaposi sarcoma mostly affects the legs and HIV-associated Kaposi sarcoma the trunk [31].

Half of patients present mucosal lesions in the mouth, larynx, pharynx and, less frequently, the nose. Lesions are purple nodules that may grow and ulcerate. Cervical lymphadenopathy or regional adenopathy may be present [37, 38].

Visceral localisation of Kaposi sarcoma may be a major concern and is more frequent in HIV-associated than non-HIV-associated Kaposi sarcoma [31]. Localisation is most frequently pulmonary and gastrointestinal. Gastrointestinal Kaposi sarcoma is mostly asymptomatic but may be responsible for bleeding.

FIGURE 2 Well delimited purple macule typical of cutaneous lesions of Kaposi sarcoma.

Pulmonary manifestations

Almost 45% of HIV-infected patients with cutaneous Kaposi sarcoma show pleural or pulmonary manifestations of Kaposi sarcoma. Conversely, 85–95% of patients with pulmonary Kaposi sarcoma also present with cutaneous involvement [39–41]. Pulmonary Kaposi sarcoma is usually asymptomatic and detected on chest radiography or bronchoscopy performed for suspected infection. When symptoms are present, they are not specific (cough or dyspnoea). Pleural pain or haemoptysis is more suggestive but less frequent. Afebrile cough with an insidious beginning, radiographic findings suggestive of oedema and cutaneous localisation of Kaposi sarcoma are suggestive of pulmonary localisation [39].

Chest radiography shows nodular opacities or masses that may be single or multiple, dense, homogenous, or ill-defined and which may merge. Also found are opacities that are linear, bilateral, peribronchovascular, perihilar, predominant in the bases and prolonged in the periphery as thin reticular opacities (fig. 3). Small or moderate, unilateral or bilateral pleural effusion is frequent [40, 42]. Alternatively, chest radiography may give normal results or may show superimposed abnormalities of Kaposi sarcoma and an opportunistic infection.

Visualisation of abnormalities seen on chest radiography is little improved with computed tomography (CT) scan. The CT scan shows bilateral, centrilobular ill-defined nodules that are more pronounced in the lower zone. The nodule is surrounded by ground-glass opacities, which form a halo. Typical peribronchovascular fusing from the pulmonary hilum, septal thickening, consolidations, mediastinal lymphadenopathy, or a small or moderate pleural effusion may be present (fig. 4) [39, 40, 42, 43].

Bronchoscopy is necessary for the diagnosis of pulmonary involvement of Kaposi sarcoma. It reveals rounded, raised, non-crumbly, red, irregularly shaped lesions from 0.2 to 1 cm in diameter on the trachea or bronchi, specifically from the carina to the bronchial division. The macroscopic aspect is sufficient for visualisation by an experienced pulmonologist (fig. 5). Analysis of bronchoalveolar lavage fluid (BALF) reveals normal cell counts but may reveal alveolar haemorrhage, which therefore excludes opportunistic infection [44, 45]. Increased HHV-8 viral load in BALF, as assessed by PCR, could have 100% sensitivity and 98% specificity [46]. Bronchial biopsy is not mandatory for diagnosis, because results may be a false negative, with a theoretical risk of bleeding. At present, the diagnosis is difficult because of the decreased prevalence of Kaposi sarcoma and the loss of experts in the field.

Thoracic Kaposi sarcoma may involve the visceral pleura. Pleural puncture reveals exudative sero-haematic or haemorrhagic fluid, with no cell predominance. Effusion may be a chylothorax in 20% of cases without pleural localisation of Kaposi sarcoma. Cytology of pleural fluid and percutaneous pleural biopsy are not helpful. When required, pleuroscopy shows typical red or purplish lesions for diagnosis [47]. In the absence of accessible bronchial lesions, surgical lung biopsy may be necessary. After BALF and CT scan evaluations, this situation is extremely rare.

Diagnosis

Cutaneous findings, CD4 count $<$200 cells·mm^{-3}, uncontrolled HIV infection, and thoracic imaging and bronchoscopy findings with BALF analysis are often sufficient for Kaposi sarcoma diagnosis [48].

DOI: 10.1183/09031936.00154212

FIGURE 3 Chest radiograph showing bilateral multiple nodular opacities, predominant in the bases in a patient with pulmonary Kaposi sarcoma.

HHV-8 serology and PCR of blood are not necessary and may give false-negative results (table 1) [10]. PCR analysis of pleural HHV-8 infection has not been demonstrated to be useful but may be helpful in diagnosis. A low HHV-8 viral load in pleura would rule out PEL [49].

Differential diagnosis

Almost no differential diagnosis exists for the disease, except in rare cases of pulmonary lymphoma (*e.g.* in a patient with cutaneous Kaposi sarcoma, peribronchovascular and septal thickening, CD4 count $<$200 cells·mm^{-3} and exclusion of opportunistic infection by BALF analysis [42]).

The most frequent differential diagnosis is opportunistic infection with, for example, *Bartonella henselae*, lymphoid interstitial pneumonia, carcinomatous lymphangitis and sarcoidosis [50]. BALF analysis is helpful and shows, in lymphoid interstitial pneumonia for instance, lymphocytic alveolitis with predominance of CD8 positivity. For alveolar haemorrhage, the most frequent differential diagnoses are cardiac insufficiency and opportunistic infection, particularly *Aspergillus* or cytomegalovirus infection [50].

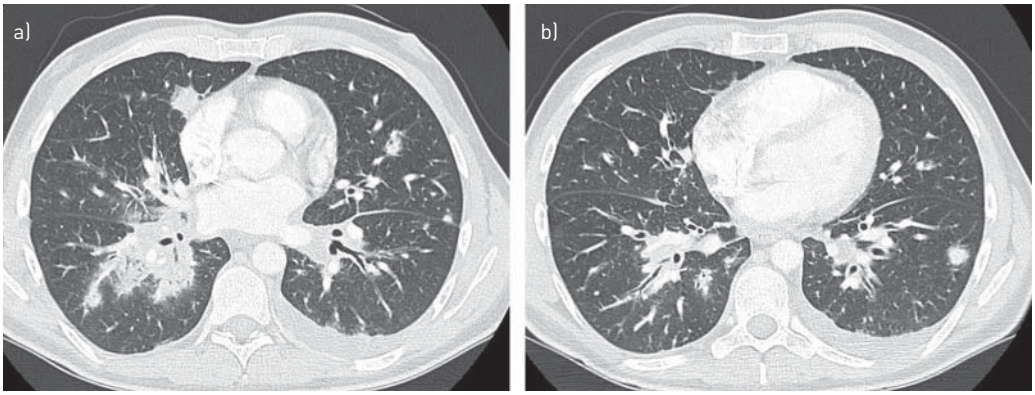

FIGURE 4 Computed tomography images showing one centrilobular ill-defined nodule surrounded by ground-glass opacities (a), peribronchovascular thickening fusing from the pulmonary hilum and a small left pleural effusion (b), all typical of Kaposi sarcoma.

FIGURE 5 Endoscopic view of bronchial localisation of Kaposi sarcoma.

Evolution and therapy

Except for a functional or vital risk of respiratory insufficiency, in Kaposi sarcoma, HIV infection must be controlled first to rapidly reverse the immunodeficiency (table 2). cART alone is generally sufficient to cure Kaposi sarcoma associated with HIV [51]. However, a few cases have been reported of paradoxical worsening soon after the beginning of cART [52]. Therapy must be evaluated after 3 months of cART with at least one protease inhibitor. Protease inhibitors are superior to other classes of antiretroviral drugs in experimental models of HHV-8 infection [53, 54]. Thus, in the absence of haemoptysis or respiratory insufficiency, with pulmonary localisation of Kaposi sarcoma, the first-line therapy is cART alone.

Anti-HHV-8 antiviral therapy (cidofovir, ganciclovir or foscarnet) has demonstrated *in vitro* activity against HHV-8 infection, but not against Kaposi sarcoma [55]. Local therapy with vinblastine, cryotherapy, laser therapy, radiotherapy or surgical removal may be considered for cutaneous Kaposi sarcoma, but has never been investigated for pulmonary Kaposi sarcoma [56].

If necessary, pulmonary Kaposi sarcoma localisations may be treated with systemic chemotherapy such as anthracycline (pegylated liposomal doxorubicin or liposomal daunorubicin), vinblastine, bleomycin or paclitaxel (table 2). Anthracyclines are well tolerated despite the risk of cardiac toxicity; response rates are almost 50%, with a median of 5 months response [57]. Chemotherapy with paclitaxel shows almost the same efficacy but can interact with protease inhibitors [58, 59]. Protease inhibitors, such as ritonavir, are among the most potent antiviral drugs and are often a component of cART [60]. Protease inhibitors are metabolised by the cytochrome P450 system. They may inhibit or induce the system and alter the

TABLE 2 Proposed recommendations for therapy of human herpesvirus (HHV)-8 lung disease during HIV infection

Disease	Antiretroviral therapy	Anti-HHV-8 antiviral therapy	Local therapy	Chemotherapy
Kaposi sarcoma	Yes	No	Possible for cutaneous lesions	Monotherapy if symptomatic patient or failure of antiretroviral therapy[#]
Multicentric Castleman's disease	Yes	Controversial	No	Etoposide ± rituximab
Primary effusion lymphoma	Yes	Controversial	For palliative care	CHOP ± methotrexate

CHOP: cyclophosphamide, adriamycin, vincristine and prednisone. [#]: paclitaxel or liposomal anthracyclins induce rapid remission with interaction between paclitaxel and protease inhibitors.

DOI: 10.1183/09031936.00154212

metabolism of other drugs, such as paclitaxel, that are metabolised by this pathway [61]. Indeed, paclitaxel exposure (the area under curve) is increased in patients receiving protease inhibitors. However, the treatment does not always result in increased toxicity [62]. The easiest alternative is to switch the protease inhibitor for another antiviral drug; if necessary, paclitaxel and a protease inhibitor may be associated, with close monitoring [63]. Bleomycin and vinblastine show poor response when used as monochemotherapy and are usually combined with pegylated liposomal doxorubicin [59]. Furthermore, chemotherapy induces additional immunodeficiency, which necessitates prophylaxis against pneumocystosis and toxoplasmosis. Haematological toxicity due to chemotherapy may require haematopoietic growth-factor therapy [64].

Other therapies that could be effective for Kaposi sarcoma, which are currently being evaluated, include interferon-α, mTOR inhibitors such as rapamycin, or angiogenesis inhibitors such as lenalidomide, bevacizumab, sunitinib or sorafenib [57, 65].

Multicentric Castleman's disease

Definition

The definition of Castleman's disease is histological: angiofollicular lymph-node hyperplasia. Localised disease, the most frequent form of Castleman's disease in non-immunocompromised patients, is not associated with HHV-8 infection. HHV-8-associated MCD is distinguished from classical hyaline-vascular or plasma cell type Castleman's disease. HHV-8 is considered the aetiological agent of most HIV-associated MCD and half of non-HIV-associated MCD [2, 66].

MCD is rare. Evaluating the prevalence of MCD after the introduction of cART in the mid-1990s has been difficult, particularly because HIV-associated MCD was described at the same time [67]. MCD may occur in patients with controlled or uncontrolled HIV infection. The largest series of MCD-associated HIV infection in France consisted of 173 patients, as compared with almost 150 000 patients living with HIV infection in France [66, 68].

Clinical examination and complementary exams

The initial presentation of MCD may suggest lymphoma with fever, polyadenopathy and hepatosplenomegaly. MCD presents outbreaks that may spontaneously resolve and questioning may reveal a previous flare that remained without diagnosis.

Cutaneous or mucous localisation of Kaposi sarcoma may be present in almost 75% of cases [69]. Nasal obstruction is frequent, and pulmonary symptoms (cough, dyspnoea and expectoration) are present in 33–75% of cases. Haemoptysis is rare. Pulmonary auscultation may show crackles [67, 69, 70]. When respiratory symptoms are present, chest radiography shows bilateral interstitial opacities that may consolidate to alveolar opacities. Mediastinal lymphadenopathy and a small pleural effusion may be present (fig. 6).

Chest CT scan shows reticular and micronodular opacities with lymphatic distribution: either subpleural, peribronchovascular or septal. Nodular or ground-glass opacities may be present. CT scan shows 1–3 cm mediastinal lymphadenopathies. A small pleural effusion may be present. CT scan results appear normal with resolution of the flare [71].

Biological tests usually show anaemia with inflammatory syndrome and C-reactive protein level is almost always >200 $mg \cdot L^{-1}$ [72]. Life-threatening forms of MCD are associated with haemophagocytic syndrome [73]. High liver enzyme levels and renal insufficiency may be present [74]. Protein electrophoresis reveals polyclonal hypergammaglobulinaemia and hypoalbuminaemia in ~50% of cases. Biological test results for almost 30% of patients show autoimmunity, by direct anti-globulin test or use of anti-cardiolipin and/or anti-phospholipid antibodies. Autoimmune manifestations are related more to MCD and not HIV. Indeed, except for idiopathic or thrombotic thrombocytopenic purpura, autoimmune diseases are rare during HIV infection.

PCR-assessed HHV-8 viral load is always increased in peripheral blood and has a good negative predictive value (table 1) [10, 72]. A high HHV-8 viral load may predict an MCD flare [75]. Viral HHV-8 load is usually 2–4 log copies per 10^5 PBMCs [28] and, thus, HHV-8 serology is not helpful.

Bronchoscopy is rarely necessary. In a series of 12 patients, none presented macroscopic abnormalities, particularly Kaposi sarcoma lesions. BALF analysis revealed increased cellular counts in five out of 11 patients and increased alveolar lymphocytes in seven out of 11. None had a simultaneous pulmonary opportunistic infection [70].

Diagnosis

MCD is generally diagnosed on histological examination of a lymph-node biopsy [76]. Results typically show follicular hyperplasia, hyalinisation and involution of germinal centres; hyperplasia of the mantle zone shows concentric rings of lymphocytes, "onion-skin layers". Increased vascularity with capillary

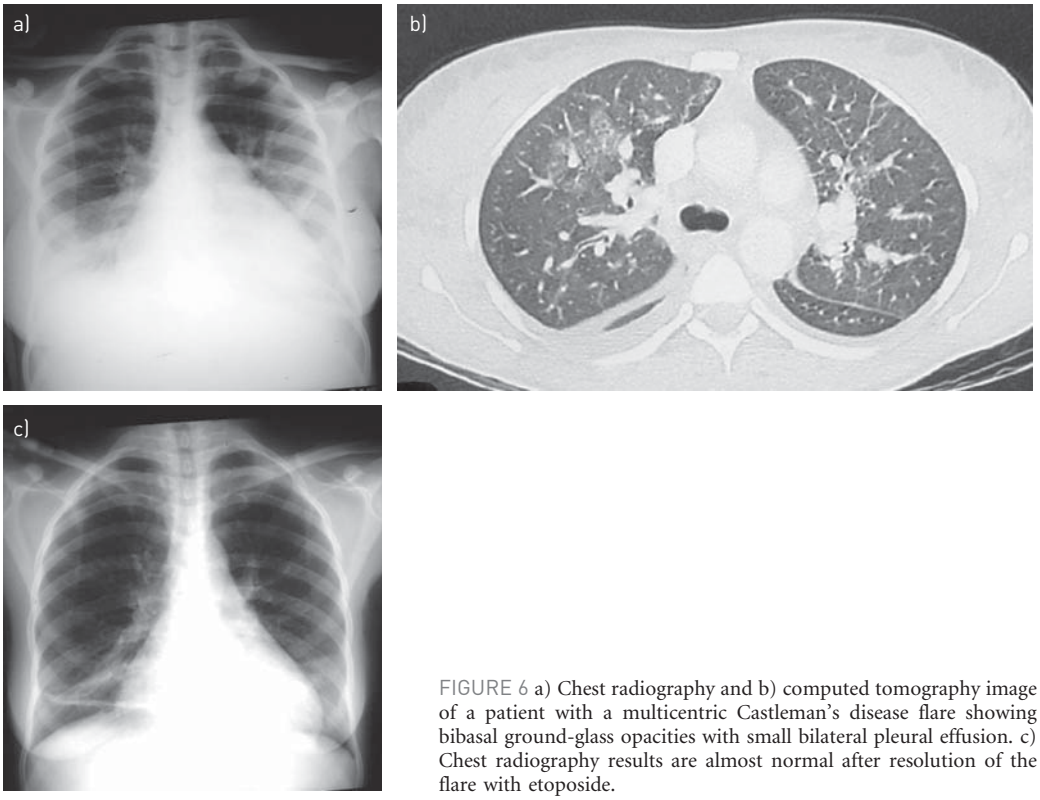

FIGURE 6 a) Chest radiography and b) computed tomography image of a patient with a multicentric Castleman's disease flare showing bibasal ground-glass opacities with small bilateral pleural effusion. c) Chest radiography results are almost normal after resolution of the flare with etoposide.

proliferation and endothelial hyperplasia is observed. Sheets of plasma cells are present in interfollicular areas. Results of only one surgical lung biopsy have been reported and showed lesions similar to those in lymph nodes [71].

HHV-8 infected cells are detected by immunohistochemistry with LANA-1 antibody. Infected cells are dispersed in the mantle zone [77, 78]. LANA assay confirms the diagnosis, particularly in difficult histological cases. HHV-8 infected cells are not infected with EBV, and *in situ* hybridisation with EBV-encoded RNA (EBER) gives negative results. EBV does not seem to play a role in MCD. Kaposi sarcoma and MCD lesions may coexist in the same lymph node in almost two-thirds of cases [79].

In MCD lesions, HHV-8 infected cells are B-cells with plasma-cell differentiation. Previously, they were called plasmablasts; however, they are naïve B-cells. The characterisation of surface immunoglobulin shows monotypic IgM-λ B-cells, but they are polyclonal [26]. B-cells may group together in a sheet of monoclonal cells, called microlymphoma. Clinical and therapeutic implications of this observation remain to be determined [78].

Differential diagnosis

The main differential diagnoses are tuberculosis and Hodgkin or non-Hodgkin lymphomas, which require a histological diagnosis. With high PCR-assessed HHV-8 viral load, HHV-8 related disease is likely and non-HHV-8 related disease unlikely. However, unusual evolution with therapy should suggest reconsidering the diagnosis in the absence of histological proof. PCR and serology are then helpful [80]. During HIV infection, pulmonary manifestations of MCD should exclude infections that justify bronchoscopy with BALF analysis [70]. Haemophagocytosis may provoke anasarca with pleural effusion. However, pleural effusion may be secondary to Kaposi sarcoma or PEL, which must be excluded by pleural fluid analysis.

Evolution and therapy

Although MCD flares may spontaneously resolve, they are likely to recur and be life-threatening without a specific therapy. A review reported a median survival of 11 months and mortality of 47% [69]. The reported causes of death were infection (24%), organ dysfunction (15%), non-Hodgkin lymphoma (15%) and MCD (9%). Furthermore, numerous reported infections or organ dysfunctions are probably secondary to uncontrolled MCD. A long delay in MCD diagnosis may be associated with poor prognosis, but has not

DOI: 10.1183/09031936.00154212

been demonstrated [69]. However, a recent series in Germany reported a mean survival of 1.5 years before 2005, but 77% 5-year survival after 2005 [81].

The risk of lymphoma used to be 10–20 times higher in patients with MCD as compared with HIV-infected patients [82]. Most lymphomas occurring after MCD are related to HHV-8 infection [82]. The risk has probably decreased since the introduction of cART and has been greatly reduced with rituximab therapy [83].

Recommendations for MCD therapy rely only on expert opinion. They suggest treating: 1) the HIV infection to reduce immunodeficiency; 2) the lymphoid proliferation; and 3) the HHV-8 infection (table 2) [76, 84].

Animal experiments confirm that co-infection with simian immunodeficiency virus is required for development of MCD [85]. MCD generally appears in patients with CD4 count <350 cells·mm^{-3}. However, the effect of cART has never been demonstrated in MCD. Moreover, numerous cases of MCD appearing soon after the initiation of cART have been reported [86]. Nevertheless, beginning cART seems necessary because active HIV replication increases immunodeficiency and particularly the risk of lymphoma. A recent review showed an increase in survival since the introduction of cART [69, 82]. Ganciclovir and cidofovir are active against HHV-8 infection *in vitro*. Cidofovir has no effect on MCD. A recent series showed transient remission with high-dose zidovudine and valganciclovir, but only 23% were long-term responders [87, 88].

MCD is not a monoclonal lymphoid proliferation, but is aggressive and lethal. This supports the use of chemotherapy. Chemotherapy may be required in an emergency and induces rapid remission. Indeed, in intensive care units, MCD diagnosis is associated with good prognosis among patients with haemophagocytosis [89]. Remission of MCD symptoms is achieved in almost 24–48 h with *i.v.* etoposide. Etoposide may be given orally once a week thereafter. However, long-term therapy with etoposide increases the risk of myelodysplasia and alternative long-term treatment should be discussed [90]. Avoiding relapse requires other therapies [69, 91]. Prolonged remission was obtained after polychemotherapy with cyclophosphamide, adriamycin, vincristine and prednisone (CHOP) or equivalent [69, 92, 93].

Therapy with rituximab, a humanised monoclonal antibody against the protein CD20 in B-cells, is attractive. Indeed, rituximab, four injections of 375 mg·m^{-2} weekly, led to prolonged MCD remission in almost 80% of cases [76, 81, 94, 95]. Overall survival of MCD has greatly improved since the use of rituximab and may be 90% at 5 years [81]. In almost half of the cases, Kaposi sarcoma lesions worsen after rituximab injection. No other side-effects have been reported. In contrast, with lymphoma-associated AIDS, rituximab is associated with a high risk of severe infection [96]. It is of note that two small series reported poor efficacy of rituximab used as first-line therapy in active MCD [49, 97].

Some MCD experts propose etoposide as first-line therapy to control disease and as a relay with multiple therapies combining ganciclovir, etoposide and rituximab, together with optimised cART [76, 84]. Corticosteroids have a partial effect in MCD but increase the risk of worsening Kaposi sarcoma lesions and are not recommended [76].

Primary effusion lymphoma

Epidemiology and definition

In 1995, HHV-8 infection was found in a particular type of mesothelium lymphoma involving the pleura, pericardium or peritoneum in immunocompromised patients [3]. It was called PEL in the World Health Organization classification, to differentiate it from solid lymphoma with secondary effusion localisation [98]. Since its first description, PEL has been described in a solid form. Solid PEL may occur as a relapse of liquid PEL or as an initial presentation [99].

PEL is a rare lymphoma corresponding to 0.5% of all lymphoma and 3% of AIDS-associated lymphoma [100]. PEL may occur in patients with virologically controlled or uncontrolled HIV infection. The mean CD4 count is 150 cells·mm^{-3} [27]. PEL has rarely been described in patients with immunodeficiency secondary to organ transplantation or in patients >80 years old [101, 102].

Clinical presentation

Patients mostly present fever, altered perfomance status and dyspnoea [27]. Pleural effusion is present in 85% of cases and is associated with ascites in 50% of cases [24]. PEL may also be revealed by a cardiac tamponade secondary to a specific pericardial localisation [27]. Hepatomegaly and splenomegaly are present in two-thirds of cases [27]. Cutaneous or mucosal localisation of Kaposi sarcoma is present in 30–70% of cases. MCD and PEL may be associated. Enlarged peripheral lymph nodes are rare. Neurological deficit or a maxillary lesion should lead to suspicion of the specific localisation of the disease [24].

Biological examination often reveals anaemia, associated in 50% of cases, with thrombocytopenia and hypoalbuminaemia [24]. Lactate dehydrogenase concentration is, in general, elevated [27]. Bone-marrow biopsy may show haemophagocytosis but rarely tumour cells [24, 27].

Pleural fluid analysis shows sero-haematic exudative fluid and this analysis is mandatory for diagnosis [27]. CT scan shows pleural effusion without pulmonary lesions or a detectable mass. A small pleural thickening may be present. Pericardial or peritoneal effusion may be present [103].

Diagnosis

No solid tumour is present and the diagnosis is by cytology, performed by a trained cytologist. Pleural biopsy is generally not required or helpful. Cells are polymorphous and large, sometimes immunoblastic, with a certain degree of plasma cell differentiation and an irregular polylobular nucleus. Cytoplasm is abundant and hyperbasophilic. Mitoses are numerous. Cells do not generally express B-cell markers (CD19 or CD20) or T-cell markers (CD3), but do express CD45, which confirms the lymphoid origin, and may express aberrant T-cell markers such as intracytoplasmic CD3 or CD4. They may coexpress activation markers, such as CD30, CD38 or CD71, MUM1, and plasma-cell markers such as CD138 [104, 105]. B-cells are monoclonal but the confirmation of monoclonality with PCR analysis is not required for diagnosis. Moreover, some techniques of clonality analysis may produce false negative results because of the numerous somatic mutations affecting the variable region of immunoglobulin genes [106].

HHV-8 infection must be confirmed by immunohistochemistry with LANA antigen on tumour cells and/or PCR evaluation of the viral load in pleural fluid (table 1). PCR typically reveals a 3–4 log ratio between pleura and blood [10]. In the blood, HHV-8 viral load is generally >4 log copies per 10^5 PBMCs [28].

In 70% of cases, tumour cells are co-infected with EBV. EBV infection is at the type 1 latency stage. Indeed, an immunohistochemistry assay with latent membrane protein is negative for tumour cells. *In situ* hybridisation with the EBER probe for tumour cells or PCR analysis of pleural fluid is required to confirm the presence of EBV [24].

Cytogenetic analysis shows a complex karyotype, or trisomy 7, 8 or 12. It never shows other structural abnormalities, such as c-Myc or Bcl-2 protein [107].

Differential diagnosis

Differentiating PEL and another lymphoma with pleural localisation may be difficult. Thus, detection of HHV-8 is helpful to differentiate PEL from other lymphomas [108, 109].

In an immunocompromised patient, pleural effusion with fever or altered performance status is more often secondary to Kaposi sarcoma or an infectious disease, such as tuberculosis, than PEL. Pleural fluid analysis does not show tumour cells and HHV-8 viral load in the pleural fluid will be weaker.

Evolution and therapy

No recommended therapy for PEL exists. Median survival is 6 months and 1-year survival is 39% [24]. Absence of cART at diagnosis is associated with poor prognosis, and optimised cART alone can have anti-tumoural activity and may lead to remission [24, 110]. A retrospective study of the literature suggested that the number of involved cavities is associated with the median survival [111]. Median survival is longer for patients with only one involved cavity than those with multiple involved cavities (18 *versus* 4 months). For patients with only one involved cavity, median survival is longer for those with pericardial and pleural involvement than those with peritoneal involvement (40, 27 and 5 months, respectively).

The usual therapy is polychemotherapy such as CHOP, with, possibly, methotrexate. Complete remission is usually achieved even with high morbidity (table 2) [24, 112]. Pleurodesis with talc or intrapleural cidofovir may be discussed in palliative situations [113].

Rituximab is not recommended because tumour cells do not express CD20 and rituximab increases immunodeficiency. Furthermore, cART interacts with chemotherapy. Indeed, chemotherapy must be performed in specialised centres.

Some cases have been reported of prolonged remission after intrapleural administration of cidofovir, an anti-HHV-8 agent [114, 115]. Other therapies, such as rapamycin, anti-vascular endothelial growth factor therapy or interferon, have been investigated or reported in anecdotal cases [24, 116, 117].

Conclusions

Respiratory manifestations of HHV-8 infection in HIV-infected patients are numerous and varied. The most frequent HHV-8 pulmonary manifestation used to be Kaposi sarcoma, but the prevalence of Kaposi

DOI: 10.1183/09031936.00154212

sarcoma has greatly decreased since the introduction of cART. Respiratory manifestations are frequent during Kaposi sarcoma, MCD or PEL. They are often the first manifestations of these diseases and may need urgent treatment. These diseases require demonstration of HHV-8 infection. Delay in diagnosis may be associated with poor prognosis in MCD and PEL. Unexplained pulmonary disease in an HIV-infected patient or other high-risk patients, such as immunosuppressed or older adults from an HHV-8 endemic country, should suggest HHV-8-associated disease. The scarcity and complexity of care justifies seeking advice from a specialised centre.

References

1 Chang Y, Cesarman E, Pessin MS, *et al.* Identification of herpesvirus-like DNA sequences in AIDS-associated Kaposi's sarcoma. *Science* 1994; 266: 1865–1869.
2 Soulier J, Grollet L, Oksenhendler E, *et al.* Kaposi's sarcoma-associated herpesvirus-like DNA sequences in multicentric Castleman's disease. *Blood* 1995; 86: 1276–1280.
3 Cesarman E, Chang Y, Moore PS, *et al.* Kaposi's sarcoma-associated herpesvirus-like DNA sequences in AIDS-related body-cavity-based lymphomas. *N Engl J Med* 1995; 332: 1186–1191.
4 Gantt S, Casper C. Human herpesvirus 8-associated neoplasms: the roles of viral replication and antiviral treatment. *Curr Opin Infect Dis* 2011; 24: 295–301.
5 Tedeschi R, Luostarinen T, De Paoli P, *et al.* Joint Nordic prospective study on human herpesvirus 8 and multiple myeloma risk. *Br J Cancer* 2005; 93: 834–837.
6 Valmary S, Dorfmüller P, Montani D, *et al.* Human γ-herpesviruses Epstein–Barr virus and human herpesvirus-8 are not detected in the lungs of patients with severe pulmonary arterial hypertension. *Chest* 2011; 139: 1310–1316.
7 Lebbé C, Agbalika F, Flageul B, *et al.* No evidence for a role of human herpesvirus type 8 in sarcoidosis: molecular and serological analysis. *Br J Dermatol* 1999; 141: 492–496.
8 Longnecker R, Neipel F. Introduction to the human γ-herpesviruses. *In*: Arvin A, Campadelli-Fiume G, Mocarski E, *et al.*, eds. Human Herpesviruses: Biology, Therapy, and Immunoprophylaxis. Cambridge, Cambridge University Press, 2007; pp. 341–359.
9 Russo JJ, Bohenzky RA, Chien MC, *et al.* Nucleotide sequence of the Kaposi sarcoma-associated herpesvirus (HHV8). *Proc Natl Acad Sci USA* 1996; 93: 14862–14867.
10 Marcelin AG, Motol J, Guihot A, *et al.* Relationship between the quantity of Kaposi sarcoma-associated herpesvirus (KSHV) in peripheral blood and effusion fluid samples and KSHV-associated disease. *J Infect Dis* 2007; 196: 1163–1166.
11 Uldrick TS, Wang V, O'Mahony D, *et al.* An interleukin-6-related systemic inflammatory syndrome in patients co-infected with Kaposi sarcoma-associated herpesvirus and HIV but without Multicentric Castleman disease. *Clin Infect Dis* 2010; 51: 350–358.
12 Yuzuriha A, Saitoh T, Koiso H, *et al.* Successful treatment of autoimmune hemolytic anemia associated with multicentric Castleman disease by anti-interleukin-6 receptor antibody (tocilizumab) therapy. *Acta Haematol* 2011; 126: 147–150.
13 Suthaus J, Stuhlmann-Laeisz C, Tompkins VS, *et al.* HHV-8-encoded viral IL-6 collaborates with mouse IL-6 in the development of multicentric Castleman disease in mice. *Blood* 2012; 119: 5173–5181.
14 Schulz TF. The pleiotropic effects of Kaposi's sarcoma herpesvirus. *J Pathol* 2006; 208: 187–198.
15 Oksenhendler E, Cazals-Hatem D, Schulz TF, *et al.* Transient angiolymphoid hyperplasia and Kaposi's sarcoma after primary infection with human herpesvirus 8 in a patient with human immunodeficiency virus infection. *N Engl J Med* 1998; 338: 1585–1590.
16 Gao SJ, Kingsley L, Hoover DR, *et al.* Seroconversion to antibodies against Kaposi's sarcoma-associated herpesvirus-related latent nuclear antigens before the development of Kaposi's sarcoma. *N Engl J Med* 1996; 335: 233–241.
17 Regamey N, Tamm M, Wernli M, *et al.* Transmission of human herpesvirus 8 infection from renal-transplant donors to recipients. *N Engl J Med* 1998; 339: 1358–1363.
18 Mesri EA, Cesarman E, Boshoff C. Kaposi's sarcoma and its associated herpesvirus. *Nat Rev Cancer* 2010; 10: 707–719.
19 Plancoulaine S, Abel L, van Beveren M, *et al.* Human herpesvirus 8 transmission from mother to child and between siblings in an endemic population. *Lancet* 2000; 356: 1062–1065.
20 Pauk J, Huang ML, Brodie SJ, *et al.* Mucosal shedding of human herpesvirus 8 in men. *N Engl J Med* 2000; 343: 1369–1377.
21 Spira TJ, Lam L, Dollard SC, *et al.* Comparison of serologic assays and PCR for diagnosis of human herpesvirus 8 infection. *J Clin Microbiol* 2000; 38: 2174–2180.
22 Burbelo PD, Issa AT, Ching KH, *et al.* Distinct profiles of antibodies to Kaposi sarcoma-associated herpesvirus antigens in patients with Kaposi sarcoma, multicentric Castleman disease, and primary effusion lymphoma. *J Infect Dis* 2010; 201: 1919–1922.
23 Mbisa GL, Miley W, Gamache CJ, *et al.* Detection of antibodies to Kaposi's sarcoma-associated herpesvirus: a new approach using K8.1 ELISA and a newly developed recombinant LANA ELISA. *J Immunol Methods* 2010; 356: 39–46.
24 Boulanger E, Gérard L, Gabarre J, *et al.* Prognostic factors and outcome of human herpesvirus 8-associated primary effusion lymphoma in patients with AIDS. *J Clin Oncol* 2005; 23: 4372–4380.
25 Gessain A, Duprez R. Spindle cells and their role in Kaposi's sarcoma. *Int J Biochem Cell Biol* 2005; 37: 2457–2465.
26 Du MQ, Liu H, Diss TC, *et al.* Kaposi sarcoma-associated herpesvirus infects monotypic (IgM lambda) but polyclonal naive B cells in Castleman disease and associated lymphoproliferative disorders. *Blood* 2001; 97: 2130–2136.
27 Boulanger E, Agbalika F, Maarek O, *et al.* A clinical, molecular and cytogenetic study of 12 cases of human herpesvirus 8 associated primary effusion lymphoma in HIV-infected patients. *Hematol J* 2001; 2: 172–179.
28 Simonelli C, Tedeschi R, Gloghini A, *et al.* Plasma HHV-8 viral load in HHV-8-related lymphoproliferative disorders associated with HIV infection. *J Med Virol* 2009; 81: 888–896.
29 Levi JE, Nascimento MC, Sumita LM, *et al.* Non-detection of human herpesvirus 8 (HHV-8) DNA in HHV-8-seropositive blood donors from three Brazilian regions. *PLoS One* 2011; 6: e23546.

30 Verma S, Nuovo GJ, Porcu P, *et al.* Epstein–Barr virus- and human herpesvirus 8-associated primary cutaneous plasmablastic lymphoma in the setting of renal transplantation. *J Cutan Pathol* 2005; 32: 35–39.
31 Hiatt KM, Nelson AM, Lichy JH, *et al.* Classic Kaposi sarcoma in the United States over the last two decades: a clinicopathologic and molecular study of 438 non-HIV-related Kaposi sarcoma patients with comparison to HIV-related Kaposi sarcoma. *Mod Pathol* 2008; 21: 572–582.
32 Kaposi M. Idiopathisches Multiples Pigmentsarkom der Haut [Idiopathic multiple pigmented sarcoma of the skin]. *Arch Dermatol Syph* 1872; 4: 265–273.
33 Portsmouth S, Stebbing J, Gill J, *et al.* A comparison of regimens based on non-nucleoside reverse transcriptase inhibitors or protease inhibitors in preventing Kaposi's sarcoma. *AIDS* 2003; 17: F17–F22.
34 Lanoy E, Spano JP, Bonnet F, *et al.* The spectrum of malignancies in HIV-infected patients in 2006 in France: the ONCOVIH study. *Int J Cancer* 2011; 129: 467–475.
35 Letang E, Almeida JM, Miró JM, *et al.* Predictors of immune reconstitution inflammatory syndrome-associated with Kaposi sarcoma in Mozambique: a prospective study. *J Acquir Immune Defic Syndr* 2010; 53: 589–597.
36 Martinez V, Caumes E. Maladie de Kaposi [Kaposi's sarcoma]. *In*: Girard P, Katlama C, Pialoux G, eds. VIH édition 2007 [HIV 2007 edition]. Rueil-Malmaison, Doin, 2007; pp. 183–194.
37 Pantanowitz L, Dezube BJ. Kaposi's sarcoma. *Ear Nose Throat J* 2004; 83: 157.
38 Singh B, Har-el G, Lucente FE. Kaposi's sarcoma of the head and neck in patients with acquired immunodeficiency syndrome. *Otolaryngol Head Neck Surg* 1994; 111: 618–624.
39 Cadranel J, Naccache J, Wislez M, *et al.* Pulmonary malignancies in the immunocompromised patient. *Respiration* 1999; 66: 289–309.
40 Restrepo CS, Martínez S, Lemos JA, *et al.* Imaging manifestations of Kaposi sarcoma. *Radiographics* 2006; 26: 1169–1185.
41 Palmieri C, Dhillon T, Thirlwell C, *et al.* Pulmonary Kaposi sarcoma in the era of highly active antiretroviral therapy. *HIV Med* 2006; 7: 291–293.
42 Gasparetto TD, Marchiori E, Lourenço S, *et al.* Pulmonary involvement in Kaposi sarcoma: correlation between imaging and pathology. *Orphanet J Rare Dis* 2009; 4: 18.
43 Traill ZC, Miller RF, Shaw PJ. CT appearances of intrathoracic Kaposi's sarcoma in patients with AIDS. *Br J Radiol* 1996; 69: 1104–1107.
44 Vincent B, Flahault A, Antoine M, *et al.* AIDS-related alveolar hemorrhage: a prospective study of 273 BAL procedures. *Chest* 2001; 120: 1078–1084.
45 Cathomas G, Tamm M, McGandy CE, *et al.* Detection of herpesvirus-like DNA in the bronchoalveolar lavage fluid of patients with pulmonary Kaposi's sarcoma. *Eur Respir J* 1996; 9: 1743–1746.
46 Tamm M, Reichenberger F, McGandy CE, *et al.* Diagnosis of pulmonary Kaposi's sarcoma by detection of human herpes virus 8 in bronchoalveolar lavage. *Am J Respir Crit Care Med* 1998; 157: 458–463.
47 Light RW, Hamm H. Pleural disease and acquired immune deficiency syndrome. *Eur Respir J* 1997; 10: 2638–2643.
48 Gallafent JH, Buskin SE, De Turk PB, *et al.* Profile of patients with Kaposi's sarcoma in the era of highly active antiretroviral therapy. *J Clin Oncol* 2005; 23: 1253–1260.
49 Marcelin AG, Aaron L, Mateus C, *et al.* Rituximab therapy for HIV-associated Castleman disease. *Blood* 2003; 102: 2786–2788.
50 Foltzer MA, Guiney WB Jr, Wager GC, *et al.* Bronchopulmonary bacillary angiomatosis. *Chest* 1993; 104: 973–975.
51 Krown SE. Highly active antiretroviral therapy in AIDS-associated Kaposi's sarcoma: implications for the design of therapeutic trials in patients with advanced, symptomatic Kaposi's sarcoma. *J Clin Oncol* 2004; 22: 399–402.
52 Godoy MC, Rouse H, Brown JA, *et al.* Imaging features of pulmonary Kaposi sarcoma-associated immune reconstitution syndrome. *AJR Am J Roentgenol* 2007; 189: 956–965.
53 Casper C, Wald A. The use of antiviral drugs in the prevention and treatment of Kaposi sarcoma, multicentric Castleman disease and primary effusion lymphoma. *Curr Top Microbiol Immunol* 2007; 312: 289–307.
54 Gantt S, Carlsson J, Ikoma M, *et al.* The HIV protease inhibitor nelfinavir inhibits Kaposi's sarcoma-associated herpesvirus replication *in vitro*. *Antimicrob Agents Chemother* 2011; 55: 2696–2703.
55 Grundhoff A, Ganem D. Inefficient establishment of KSHV latency suggests an additional role for continued lytic replication in Kaposi sarcoma pathogenesis. *J Clin Invest* 2004; 113: 124–136.
56 Sullivan RJ, Pantanowitz L, Casper C, *et al.* HIV/AIDS: epidemiology, pathophysiology, and treatment of Kaposi sarcoma-associated herpesvirus disease: Kaposi sarcoma, primary effusion lymphoma, and multicentric Castleman disease. *Clin Infect Dis* 2008; 47: 1209–1215.
57 Sullivan RJ, Pantanowitz L. New drug targets in Kaposi sarcoma. *Expert Opin Ther Targets* 2010; 14: 1355–1366.
58 Bundow D, Aboulafia DM. Potential drug interaction with paclitaxel and highly active antiretroviral therapy in two patients with AIDS-associated Kaposi sarcoma. *Am J Clin Oncol* 2004; 27: 81–84.
59 Cianfrocca M, Lee S, Von Roenn J, *et al.* Randomized trial of paclitaxel *versus* pegylated liposomal doxorubicin for advanced human immunodeficiency virus-associated Kaposi sarcoma: evidence of symptom palliation from chemotherapy. *Cancer* 2010; 116: 3969–3977.
60 Jacobson LP, Yamashita TE, Detels R, *et al.* Impact of potent antiretroviral therapy on the incidence of Kaposi's sarcoma and non-Hodgkin's lymphomas among HIV-1-infected individuals. Multicenter AIDS Cohort Study. *J Acquir Immune Defic Syndr* 1999; 21: Suppl. 1, S34–S41.
61 Dixit V, Hariparsad N, Li F, *et al.* Cytochrome P450 enzymes and transporters induced by anti-human immunodeficiency virus protease inhibitors in human hepatocytes: implications for predicting clinical drug interactions. *Drug Metab Dispos* 2007; 35: 1853–1859.
62 Cianfrocca M, Lee S, Von Roenn J, *et al.* Pilot study evaluating the interaction between paclitaxel and protease inhibitors in patients with human immunodeficiency virus-associated Kaposi's sarcoma: an Eastern Cooperative Oncology Group (ECOG) and AIDS Malignancy Consortium (AMC) trial. *Cancer Chemother Pharmacol* 2011; 68: 827–833.
63 Tulpule A, Groopman J, Saville MW, *et al.* Multicenter trial of low-dose paclitaxel in patients with advanced AIDS-related Kaposi sarcoma. *Cancer* 2002; 95: 147–154.
64 Bower M, Collins S, Cottrill C, *et al.* British HIV Association guidelines for HIV-associated malignancies 2008. *HIV Med* 2008; 9: 336–388.

 DOI: 10.1183/09031936.00154212

65 Di Lorenzo G, Konstantinopoulos PA, Pantanowitz L, *et al.* Management of AIDS-related Kaposi's sarcoma. *Lancet Oncol* 2007; 8: 167–176.
66 Oksenhendler E. Maladie(s) de Castleman [Castleman disease(s)]. *In*: Traité des Maladies et Syndromes Systémiques [Treaty of Systemic Syndromes and Diseases]. Paris, Médecine-Sciences F, 2008; pp. 917–927.
67 Oksenhendler E, Duarte M, Soulier J, *et al.* Multicentric Castleman's disease in HIV infection: a clinical and pathological study of 20 patients. *AIDS* 1996; 10: 61–67.
68 Yeni P. Prise en charge médicale des personnes infectées par le VIH [Medical Care of Persons Infected With HIV]. Paris, Direction de l'information légale et administrative, 2010. Available from www.sante.gouv.fr/rapport-2010-sur-la-prise-en-charge-medicale-des-personnes-infectees-par-le-vih-sous-la-direction-du-pr-patrick-yeni.html
69 Mylona EE, Baraboutis IG, Lekakis LJ, *et al.* Multicentric Castleman's disease in HIV infection: a systematic review of the literature. *AIDS Rev* 2008; 10: 25–35.
70 Guihot A, Couderc LJ, Agbalika F, *et al.* Pulmonary manifestations of multicentric Castleman's disease in HIV infection: a clinical, biological and radiological study. *Eur Respir J* 2005; 26: 118–125.
71 Guihot A, Couderc LJ, Rivaud E, *et al.* Thoracic radiographic and CT findings of multicentric Castleman disease in HIV-infected patients. *J Thorac Imaging* 2007; 22: 207–211.
72 Oksenhendler E, Carcelain G, Aoki Y, *et al.* High levels of human herpesvirus 8 viral load, human interleukin-6, interleukin-10, and C reactive protein correlate with exacerbation of multicentric Castleman disease in HIV-infected patients. *Blood* 2000; 96: 2069–2073.
73 Henter JI, Horne A, Aricó M, *et al.* HLH-2004: diagnostic and therapeutic guidelines for hemophagocytic lymphohistiocytosis. *Pediatr Blood Cancer* 2007; 48: 124–131.
74 El Karoui K, Vuiblet V, Dion D, *et al.* Renal involvement in Castleman disease. *Nephrol Dial Transplant* 2011; 26: 599–609.
75 Stebbing J, Adams C, Sanitt A, *et al.* Plasma HHV8 DNA predicts relapse in individuals with HIV-associated multicentric Castleman disease. *Blood* 2011; 118: 271–275.
76 Oksenhendler E. HIV-associated multicentric Castleman disease. *Curr Opin HIV AIDS* 2009; 4: 16–21.
77 Dupin N, Diss TL, Kellam P, *et al.* HHV-8 is associated with a plasmablastic variant of Castleman disease that is linked to HHV-8-positive plasmablastic lymphoma. *Blood* 2000; 95: 1406–1412.
78 Du MQ, Bacon CM, Isaacson PG. Kaposi sarcoma-associated herpesvirus/human herpesvirus 8 and lymphoproliferative disorders. *J Clin Pathol* 2007; 60: 1350–1357.
79 Naresh KN, Rice AJ, Bower M. Lymph nodes involved by multicentric Castleman disease among HIV-positive individuals are often involved by Kaposi sarcoma. *Am J Surg Pathol* 2008; 32: 1006–1012.
80 Risdall RJ, McKenna RW, Nesbit ME, *et al.* Virus-associated hemophagocytic syndrome: a benign histiocytic proliferation distinct from malignant histiocytosis. *Cancer* 1979; 44: 993–1002.
81 Hoffmann C, Schmid H, Müller M, *et al.* Improved outcome with rituximab in patients with HIV-associated multicentric Castleman disease. *Blood* 2011; 118: 3499–3503.
82 Oksenhendler E, Boulanger E, Galicier L, *et al.* High incidence of Kaposi sarcoma-associated herpesvirus-related non-Hodgkin lymphoma in patients with HIV infection and multicentric Castleman disease. *Blood* 2002; 99: 2331–2336.
83 Gérard L, Michot JM, Burcheri S, *et al.* Rituximab decreases the risk of lymphoma in patients with HIV-associated multicentric Castleman disease. *Blood* 2012; 119: 2228–2233.
84 Bower M. How I treat HIV-associated multicentric Castleman disease. *Blood* 2010; 116: 4415–4421.
85 Wong SW, Bergquam EP, Swanson RM, *et al.* Induction of B cell hyperplasia in simian immunodeficiency virus-infected rhesus macaques with the simian homologue of Kaposi's sarcoma-associated herpesvirus. *J Exp Med* 1999; 190: 827–840.
86 Zietz C, Bogner JR, Goebel FD, *et al.* An unusual cluster of cases of Castleman's disease during highly active antiretroviral therapy for AIDS. *N Engl J Med* 1999; 340: 1923–1924.
87 Berezne A, Agbalika F, Oksenhendler E. Failure of cidofovir in HIV-associated multicentric Castleman disease. *Blood* 2004; 103: 4368–4369.
88 Uldrick TS, Polizzotto MN, Aleman K, *et al.* High-dose zidovudine plus valganciclovir for Kaposi sarcoma herpesvirus-associated multicentric Castleman disease: a pilot study of virus-activated cytotoxic therapy. *Blood* 2011; 117: 6977–6986.
89 Buyse S, Teixeira L, Galicier L, *et al.* Critical care management of patients with hemophagocytic lymphohistiocytosis. *Intensive Care Med* 2010; 36: 1695–1702.
90 Boshoff C, Begent RH, Oliver RT, *et al.* Secondary tumours following etoposide containing therapy for germ cell cancer. *Ann Oncol* 1995; 6: 35–40.
91 Scott D, Cabral L, Harrington WJ Jr. Treatment of HIV-associated multicentric Castleman's disease with oral etoposide. *Am J Hematol* 2001; 66: 148–150.
92 Schmidt SM, Raible A, Kortüm F, *et al.* Successful treatment of multicentric Castleman's disease with combined immunochemotherapy in an AIDS patient with multiorgan failure. *Leukemia* 2008; 22: 1782–1785.
93 Bestawros A, Michel R, Séguin C, *et al.* Multicentric Castleman's disease treated with combination chemotherapy and rituximab in four HIV-positive men: a case series. *Am J Hematol* 2008; 83: 508–511.
94 Gérard L, Bérezné A, Galicier L, *et al.* Prospective study of rituximab in chemotherapy-dependent human immunodeficiency virus associated multicentric Castleman's disease: ANRS 117 CastlemaB Trial. *J Clin Oncol* 2007; 25: 3350–3356.
95 Bower M, Powles T, Williams S, *et al.* Brief communication: rituximab in HIV-associated multicentric Castleman disease. *Ann Intern Med* 2007; 147: 836–839.
96 Kaplan LD, Lee JY, Ambinder RF, *et al.* Rituximab does not improve clinical outcome in a randomized phase 3 trial of CHOP with or without rituximab in patients with HIV-associated non-Hodgkin lymphoma: AIDS-Malignancies Consortium Trial 010. *Blood* 2005; 106: 1538–1543.
97 Buchler T, Dubash S, Lee V, *et al.* Rituximab failure in fulminant multicentric HIV/human herpesvirus 8-associated Castleman's disease with multiorgan failure: report of two cases. *AIDS* 2008; 22: 1685–1687.
98 Swerdlow SH, Campo E, Harris NL, *et al.* WHO Classification of Tumours of Haematopoietic and Lymphoid Tissues. 4th Edn. Geneva, WHO Press, 2008; p. 439.

99 Boulanger E, Brière J, Gaulard P, *et al.* HHV8-related non-Hodgkin's lymphoma of the spermatic cord in a patient with HIV-associated multicentric Castleman disease. *Am J Hematol* 2003; 72: 70–71.
100 Carbone A, Gaidano G. HHV-8-positive body-cavity-based lymphoma: a novel lymphoma entity. *Br J Haematol* 1997; 97: 515–522.
101 Schulz TF. Epidemiology of Kaposi's sarcoma-associated herpesvirus/human herpesvirus 8. *Adv Cancer Res* 1999; 76: 121–160.
102 Régnier-Rosencher E, Barrou B, Marcelin AG, *et al.* Lymphome des séreuses chez le transplante rénal: deux cas [Primary effusion lymphoma in two kidney transplant recipients]. *Ann Dermatol Venereol* 2010; 137: 285–289.
103 Morassut S, Vaccher E, Balestreri L, *et al.* HIV-associated human herpesvirus 8-positive primary lymphomatous effusions: radiologic findings in six patients. *Radiology* 1997; 205: 459–463.
104 Carbone A, Gloghini A, Larocca LM, *et al.* Expression profile of MUM1/IRF4, BCL-6, and CD138/syndecan-1 defines novel histogenetic subsets of human immunodeficiency virus-related lymphomas. *Blood* 2001; 97: 744–751.
105 Gaidano G, Carbone A. Primary effusion lymphoma: a liquid phase lymphoma of fluid-filled body cavities. *Adv Cancer Res* 2001; 80: 115–146.
106 Fais F, Gaidano G, Capello D, *et al.* Immunoglobulin V region gene use and structure suggest antigen selection in AIDS-related primary effusion lymphomas. *Leukemia* 1999; 13: 1093–1099.
107 Luan SL, Boulanger E, Ye H, *et al.* Primary effusion lymphoma: genomic profiling revealed amplification of *SELPLG* and *CORO1C* encoding for proteins important for cell migration. *J Pathol* 2010; 222: 166–179.
108 Carbone A, Gloghini A, Vaccher E, *et al.* Kaposi's sarcoma-associated herpesvirus DNA sequences in AIDS-related and AIDS-unrelated lymphomatous effusions. *Br J Haematol* 1996; 94: 533–543.
109 Galicier L, Fieschi C, Borie R, *et al.* Intensive chemotherapy regimen (LMB86) for St Jude stage IV AIDS-related Burkitt lymphoma/leukemia: a prospective study. *Blood* 2007; 110: 2846–2854.
110 Oksenhendler E, Clauvel JP, Jouveshomme S, *et al.* Complete remission of a primary effusion lymphoma with antiretroviral therapy. *Am J Hematol* 1998; 57: 266.
111 Castillo JJ, Shum H, Lahijani M, *et al.* Prognosis in primary effusion lymphoma is associated with the number of body cavities involved. *Leuk Lymphoma* 2012; 53: 2378–2382.
112 Boulanger E, Daniel MT, Agbalika F, *et al.* Combined chemotherapy including high-dose methotrexate in KSHV/HHV8-associated primary effusion lymphoma. *Am J Hematol* 2003; 73: 143–148.
113 Luppi M, Trovato R, Barozzi P, *et al.* Treatment of herpesvirus associated primary effusion lymphoma with intracavity cidofovir. *Leukemia* 2005; 19: 473–476.
114 Carbone A, Cesarman E, Gloghini A, *et al.* Understanding pathogenetic aspects and clinical presentation of primary effusion lymphoma through its derived cell lines. *AIDS* 2010; 24: 479–490.
115 Halfdanarson TR, Markovic SN, Kalokhe U, *et al.* A non-chemotherapy treatment of a primary effusion lymphoma: durable remission after intracavitary cidofovir in HIV negative PEL refractory to chemotherapy. *Ann Oncol* 2006; 17: 1849–1850.
116 Boulanger E, Meignin V, Oksenhendler E. Bortezomib (PS-341) in patients with human herpesvirus 8-associated primary effusion lymphoma. *Br J Haematol* 2008; 141: 559–561.
117 Gasperini P, Tosato G. Targeting the mammalian target of Rapamycin to inhibit VEGF and cytokines for the treatment of primary effusion lymphoma. *Leukemia* 2009; 23: 1867–1874.

 DOI: 10.1183/09031936.00154212