

Primary malignant non-Hodgkin's lymphoma of the lung arising in mucosa-associated lymphoid tissue (MALT)

A. Roggeri*, L. Agostini*, G. Vezzani*, E. Sabattini**, L. Serra#

Primary malignant non-Hodgkin's lymphoma of the lung arising in mucosa-associated lymphoid tissue (MALT). A. Roggeri, L. Agostini, G. Vezzani, E. Sabattini, L. Serra.

ABSTRACT: We describe a 10 yr follow-up of a patient with a primary malignant non-Hodgkin's lymphoma of the lung, arising in mucosa-associated lymphoid tissue (MALT). Although the patient was not treated with chemotherapy or radiotherapy, no peripheral spread occurred, confirming that MALT-associated lymphomas apparently remain localized until late in the course of the disease.

Eur Respir J., 1993, 6, 138-140.

* Pulmonary Division, Arcispedale S. Maria Nuova, Reggio Emilia, Italy. ** Haemolymphopathology Unit, Institute of Haematology-II, Service of Pathological anatomy, Bologna University, Italy. # Pathology Dept, Arcispedale S. Maria Nuova, Reggio Emilia, Italy.

Correspondence: A. Roggeri, Divisione Pneumologica, Arcispedale S. Maria Nuova, Viale Risorgimento 80, 42100 Reggio Emilia, Italy.

Keywords: Immunohistochemistry; lymphoid interstitial pneumonia; mucosa-associated lymphoid tissue; pseudolymphoma; pulmonary lymphoma.

Received: February 11, 1992; accepted after revision September 12, 1992

Primary malignant non-Hodgkin's lymphomas arising in mucosa-associated lymphoid tissue (MALT) develop most frequently in the stomach, but also in the bowel, salivary glands, larynx, thyroid gland and lung [1-6].

Interestingly, MALT-associated malignant lymphomas tend to remain localized for long periods, hence, sometimes raising doubts about their malignant nature [1, 2, 4].

Some investigators define early stage MALT-associated malignant lymphomas as pseudolymphoma, implying absence of malignancy [5]. By contrast, others consider pseudolymphoma or lymphoid interstitial pneumonia as an early stage of MALT-lymphomas [1-3, 6]. As thyroid and salivary gland lymphomas may develop from inflammatory processes [1], the separation between pseudolymphomas and/or lymphoid pneumonia from early MALT lymphomas may be difficult.

We describe a case of pulmonary malignant non-Hodgkin's lymphoma, belonging to the MALT lymphoma group, in an elderly lady, whose disease course was followed for almost 10 yrs, without any spread of the disease outside the lungs and hilar lymph nodes.

Case report

A 77 yr old Caucasian woman was first admitted to our hospital in April 1982, because of a right lung

consolidation detected seven months previously. Her medical history was unremarkable.

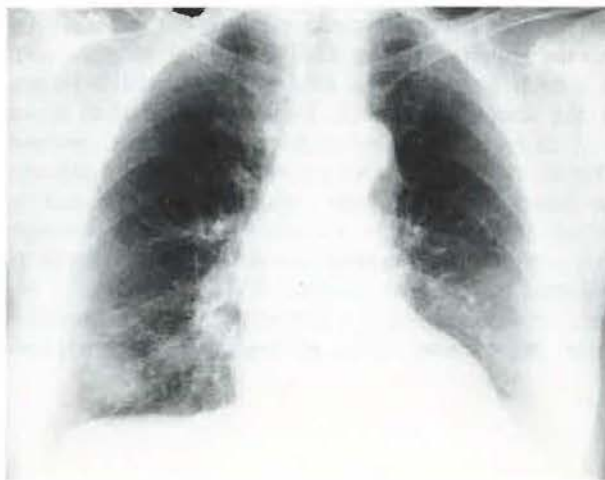

Fig. 1. - Chest roentgenogram, March 1982, a few days before the first hospitalization.

The patient was asymptomatic, but the chest roentgenogram (fig. 1) showed a bulky nodule in the right lower lobe and a poorly-defined, small nodule in the left lower lobe.

A transthoracic thin-needle aspirate from the right lung mass showed abundant cellular material,

composed of small, mature lymphoid cells with plasmacytoid appearance, associated with a few neutrophils, epithelioid histiocytes, sometimes multinucleated, and ciliated epithelial cells. The cytological specimen was considered by the pathologist to be non-conclusive and consistent with either inflammatory infiltrate or with malignant lymphoma. No immunocytochemistry technique was available in the hospital at that time.

In April 1987, a chest X-ray film showed multiple, bilateral, bulky nodules, mediastinal enlargement and obliteration of the left costophrenic angle (fig. 2). In May 1989, a second transthoracic thin-needle aspirate was performed and findings were similar to those of 1982.

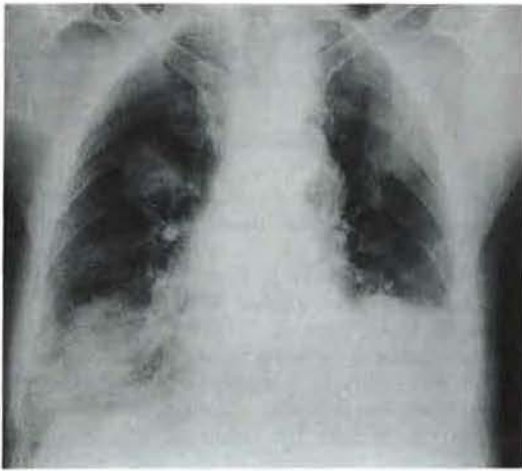


Fig. 2. - Standard chest X-ray film, April 1987, demonstrating increase in number and size of the multiple bilateral pulmonary opacities.

Steroid therapy produced a temporary decrease in the size of the nodules in the upper pulmonary lobes. The patient died in February 1991, due to heart failure after recurrent episodes of pulmonary oedema.

Autopsy was performed 24 h after death. Macroscopically, the lungs showed diffuse oedema and several indistinct parenchymal areas of consolidation. In addition, there were scattered apical and basal confluent, well-delimited nodules in both lungs. These nodules were firm, greyish-pink, with a maximum diameter of 9-10 cm.

Specimens from internal organs were placed in buffered formalin, embedded in paraffin and cut 5 μ thick. The microtome slices were stained with haematoxylineosin, Gomori's silver impregnation, periodic acid-Schiff (PAS) with and without diastase digestion and Giemsa-Lennert.

Representative sections were tested with monoclonal antibodies. The peroxidase anti-peroxidase (PAP) and the alkaline phosphatase anti-alkaline phosphatase (APAAP) methods were applied for the detection of the monoclonal antibodies employed (L26, UCHL1, 4KB5, MNF116; Dakopatts, Denmark), (MT1; Clonab, Biotest Diagnostic, Frankfurt, FRG).

L26 and 4KB5 monoclonal antibodies recognize antigens expressed by most of the B-lymphocytes; UCHL1 and MT1 are antibodies against antigens of the T-lymphocytes; MNF116 is a monoclonal antibody against cytokeratin, an antigen expressed by epithelial cells.

Microscopically, we observed multiple, confluent foci of bronchopneumonia and diffuse pulmonary acute oedema. In addition, the confluent nodules observed at macroscopic examination consisted of a population of small lymphoid cells impinging upon the normal bronchoalveolar structure of the lung. At the periphery of the nodules, the lymphoid population broadened the interalveolar septa and filled the alveolar spaces. These small lymphoid cells were characterized by a moderate rim of cytoplasm and round-to-oval nuclei with inconspicuous nucleoli.

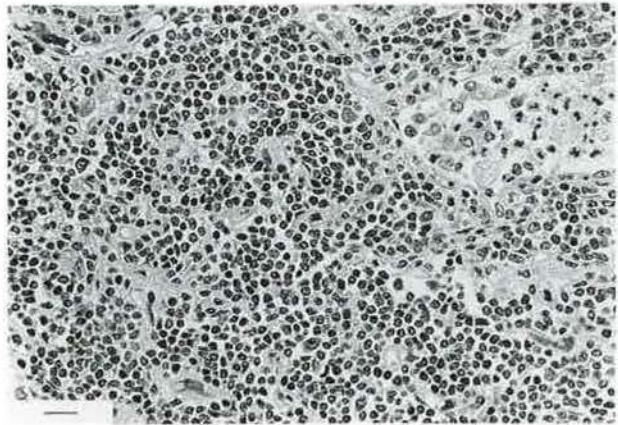


Fig. 3. - Histological section of a pulmonary nodule from autopsy material. Proliferation of small lymphoid cells, with lymphoplasmacytoid features, encroaching upon the normal lung parenchyma. In the upper right corner, an alveolar space containing some polymorphonuclear leucocytes is discernible (haematoxylin and eosin stain, bar=20 μ). (Original magnification 250 \times).

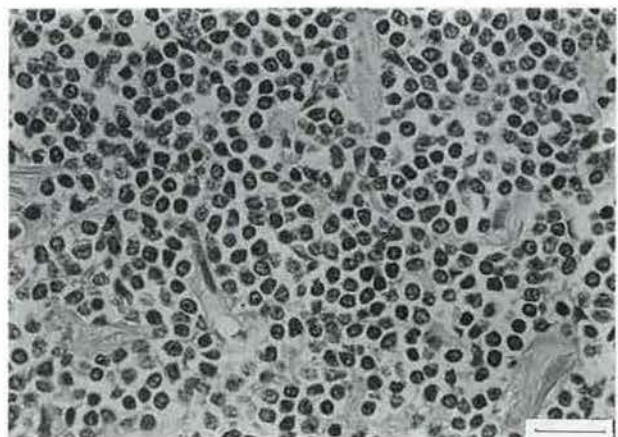


Fig. 4. - High magnification of a pulmonary nodule. The lymphoid population consists of small-sized cells, with round-to-oval nuclei and a moderate rim of cytoplasm. Many cells show lymphoplasmacytoid features (haematoxylin and eosin stain, bar=20 μ). (Original magnification 500 \times).

Sometimes, the cells showed lymphoplasmacytoid features (fig. 3 and 4). Mitotic figures were rare. In some fields, a few blasts were comprised within the small lymphoid population. However, blasts were numerous in the peripheral and medullary sinuses of the only hilar lymph node involved. At immunohistochemistry, the neoplastic cells expressed the CD20 (L26) and CD45RA (4KB5) antigens, whereas they were negative for the CD45RO (UCHL1) and CD43 (MT1) antigens. The monoclonal antibody against cytokeratins (MNF116) indicated several lympho-epithelial lesions.

Microscopic examination of the liver, bone marrow, spleen and nasopharynx showed no lymphomatous involvement. The myocardium showed diffuse interstitial fibrosis and atrophy, with focal myocytolysis.

On the basis of the above morphological and immunohistochemical features, we diagnosed a primary malignant non-Hodgkin's lymphoma derived from the B-cell component of the mucosal-associated lymphoid tissue of the lung, with hilar lymph node involvement but no peripheral spread. The lesion showed low grade malignancy in the lung, with focal transition to a high grade tumour in the lymph node.

A retrospective evaluation of the thin-needle aspirate performed in our patient in 1982 showed that the monotonous lymphoid population was probably lymphomatous almost 10 yrs before death, as it was cytologically identical to the one found at autopsy.

Discussion

We describe a 10 yr follow-up of an elderly lady with multiple opacities in both lung fields, in whom the diagnosis of a MALT primary malignant non-Hodgkin's lymphoma of the lung could be established only at autopsy. A survey of primary pulmonary lymphomas [6] shows that the age of the patients ranges 40–79 yrs, with a mean age of 54 yrs. Men are affected more frequently, with a male to female ratio of about 2:1.

The case illustrates the difficulties in establishing the diagnosis [7–9], and shows that this kind of malignancy may remain localized for several years.

The latter observation is important from the clinical point of view, because it suggests that MALT

lymphomas may not need systemic treatment. A local therapeutic approach with surgery or radiotherapy, when feasible, can offer a favourable outcome [1, 2, 4].

Immunohistochemistry is helpful in distinguishing this disease from reactive lymphoid infiltration. Reactive infiltrates are made up of polyclonal lymphoid cells, while malignant lymphomas consist of monotypic elements [1, 4, 5].

Today, a prompt diagnosis of malignant lymphoma can be obtained *in vivo*. In recent years new techniques, such as gene-translocation and immunocytochemistry have become available, allowing a better characterization of cells obtained with low-risk procedures such as thin-needle aspiration.

Acknowledgements: The authors wish to thank L.M. Fabbri and S. Pileri for critically reviewing the manuscript. They are very indebted to C. Fontanesi for her skilful secretarial assistance.

References

1. Isaacson PG, Spencer J. – Malignant lymphoma of mucosa-associated lymphoid tissue. *Histopathology*, 1987; 11: 445–462.
2. Isaacson PG, Spencer J, Finn T. – Primary B-cell gastric lymphoma. *Hum Pathol*, 1986; 17: 72–82.
3. Diebold J, Audouin J, Viry B, *et al.* – Primary lymphoplasmacytic lymphoma of the larynx: a rare localization of MALT-type lymphoma. *Ann Otol Rhinol Laryngol*, 1990; 99: 577–580.
4. Herbert A, Wright DH, Isaacson PG, Smith JL. – Primary malignant lymphoma of the lung: histopathologic and immunologic evaluation of nine cases. *Hum Pathol*, 1984; 15: 415–422.
5. Kennedy JL, Nathwani BN, Burke JS, Hill LR, Rappaport H. – Pulmonary lymphomas and other pulmonary lymphoid lesions. *Cancer*, 1985; 56: 539–552.
6. Addis BJ, Hyjek E, Isaacson PG. – Primary pulmonary lymphoma: a reappraisal of its histogenesis and its relationship to pseudolymphoma and lymphoid interstitial pneumonia. *Histopathology*, 1988; 13: 1–17.
7. Campbell JH, Raina V, Banham SW, Cunningham D, Soukop M. – Pulmonary infiltrates: diagnostic problems in lymphoma. *Postgrad Med J*, 1989; 65: 881–884.
8. Case records of the Massachusetts General hospital. (Case 28, 1989). *N Engl J Med*, 1989; 321: 102–110.
9. Roggeri A, Prandi S, Iori I. – Pulmonary involvement in non-Hodgkin's malignant lymphomas. *Chest*, 1991; 99: 527.