

Multiple pulmonary nodules

C. Tulippe-Hecq, A. Zgheib, G. Borlée-Hermans, M. Radermecker

Case report

A 35 year old Caucasian female housekeeper was admitted to our hospital on October 2, 1985 for investigation of pulmonary nodules discovered three weeks previously on a routine chest radiogram. Careful examination of the X-ray revealed four nodules of about 8 mm in diameter scattered in the middle and lower part of the left lung and in the middle and upper lobes of the right lung (fig. 1).

The patient's only complaint was a transient and mild basal left chest pain. She did not give any history of pulmonary tuberculosis, exposure to dusts, contact with sick persons, recent travel or allergy. She had been smoking 15 cigarettes daily for 13 yrs and was not taking any drugs. In April 1983, in another clinic, she underwent a hysterectomy for fibromyoma and, two weeks later, she presented a clinically well-documented chickenpox with respiratory symptoms. No chest radiogram was taken at that time but the X-ray before hysterectomy was reported normal.

On admission, physical examination, routine laboratory tests, urinalysis and electrocardiogram (ECG) were within normal limits. No calcification or cavitation was seen on the tomograms and on the chest computerized tomography (CT)-scans. Examinations of sputum and gastric contents for cytological abnormalities, acid-fast bacilli and fungi were negative. Intradermal injection of tuberculin purified protein derivative (5 U PPD) or of sensitins (Pasteur Institute, Paris) were negative. An exhaustive study of the patient's immune function, determination of tumour markers and serology for *Legionella*, *Mycoplasma*, *Chlamydia*, *Rickettsia* and viruses were negative except for high varicella antibody titres (1/12,840 immunoglobulin G (IgG) by enzyme-linked immuno-adsorbent assay (ELISA) method which were consistent with a persistent infection. Fibre-optic bronchoscopy displayed no abnormality. Cytology and cultures of the bronchoalveolar lavage fluid for pathogens were negative.

Owing to the patient's age and the possibility of malignancy, an open lung biopsy was performed. During surgery, multiple small nodules were seen on the visceral surface of the pleura and palpated in the pulmonary tissue. Two nodules of 4 and 8 mm in diameter were removed. Histological examination showed two well-circumscribed, necrotic granulomas surrounded by normal pulmonary parenchyma (fig. 2). Central necrosis contained a few calcified deposits and was surrounded by a dense fibrohyaline stroma. The outer portion of the nodules contained some lymphocytes, plasma cells and a few giant cells (fig. 3). Specific stainings and bacteriological cultures for *Mycobacteria* and fungi were negative. Such granulomatous lesions can be found in many pulmonary diseases.

Depts of Pneumology and Pathology, C.H.U. du Sart-Tilman, State University of Liège, B-4000 Liège, Belgium.

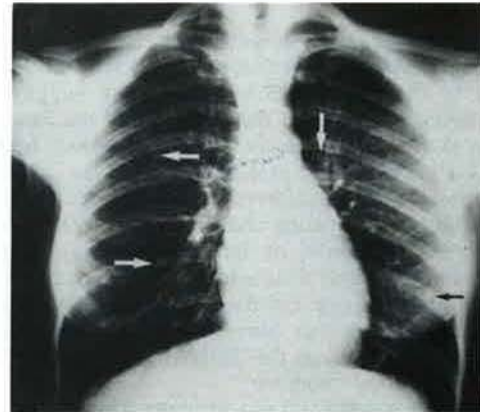


Fig. 1. - Chest X-ray showing small nodular opacities in the right upper and middle lobes and in the left lower lobe.

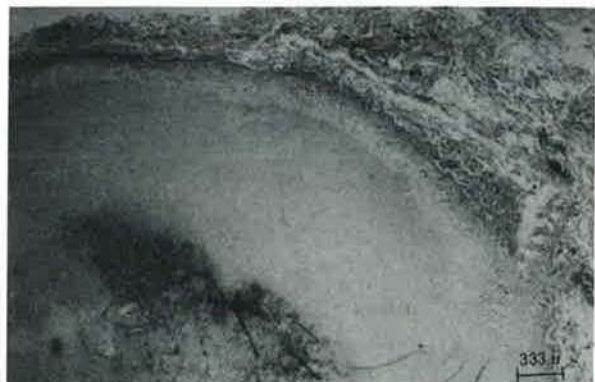

Fig. 2. - A nodular lesion showing central necrosis with calcifications surrounded by a dense fibrous tissue. The alveolar architecture is almost preserved (haematoxylin and eosin).



Fig. 3. - Higher magnification of the periphery of the nodule showing, outside a dense fibrous tissue surrounded by an inflammatory reaction made of lymphocytes, some plasma cells and a few giant cells (haematoxylin and eosin).

For diagnosis: turn over

Case for diagnosis

In view of the clinical history and following re-examination of the biopsy, the pathologist considered the granulomas fully consistent with a diagnosis of healing chickenpox nodules.

Two years after diagnosis, the patient remains asymptomatic. Control X-rays and CT-scans show a progressive calcification of the nodules.

Discussion

At first glance, the patient's chest X-ray showed four well margined, non-calcified small nodules in the lower regions of the lungs which were highly suggestive of metastatic carcinoma. But the histology of the lesions, the serology showing high titres of specific antibody IgM 1/40, and IgG 1/12,840, the 2 year follow-up of the patient and the progressive calcification of the lesions, left no doubt as to the diagnosis of healing chickenpox nodules. Secondary deposits, Mycobacterial or fungal infections, pneumococcosis, sarcoidosis and rheumatoid arthritis are the principal causes of multiple, non-calcified nodules in the lungs. This observation shows that chronic chickenpox granuloma should be considered in the differential diagnosis of multiple, non-calcified nodules.

Chickenpox is relatively rare in adults. The varicella zoster virus may invade the lung and cause an acute diffuse pneumonia in about 15% of adults generally 2-5 days after the skin rash [1-6]. Radiological aspects of acute pulmonary chickenpox vary widely, the most common form of presentation is, however, a diffuse acinar or nodular pattern [7]. Acinar or nodular opacities tend to disappear in a few weeks [3-5, 7-9]. However, chest X-rays taken months or years after pulmonary chickenpox has healed may show

persistent pulmonary nodules in asymptomatic subjects [7]. These nodules are generally numerous and calcified. Calcified and non-calcified lesions may be present in the same patient [8]. With time, the number of calcified foci tends to increase [5, 6, 8, 10]. Tiny widespread calcifications throughout both lungs are commonly observed 3-4 yrs later [5, 7-9], however they may appear earlier [7, 9] after an acute varicella in adults. Calcifications tend to be multiple, generally in the lower half of the lung [5-10] and 2 or 3 mm in diameter (larger than those in miliary tuberculosis).

References

1. Weinstein L, Meade RH. - Respiratory manifestations of chickenpox. *Arch Intern Med*, 1956, 98, 91.
2. Weber, Pellechia. - Varicella pneumonia. Study of prevalence in adult men. *J Am Med Assoc*, 1965, 192, 228-229.
3. Mermelstein RH, Freireich AW. - Varicella pneumonia. *Ann Intern Med*, 1961, 55, 456-463.
4. Triebwasser JH, Harris RE, Bryand RE, Rhoades ER. - Varicella pneumonia in adults. *Medicine*, 1967, 46, 409-423.
5. Stevens W, Vermeire P, Van de Steen R. - Pulmonary calcifications and varicella. *Acta Clinica Belgica*, 1977, 32, 264-270.
6. Rouffiat J, Fayolle M, Langumier J, Kerzbaum S. - Mili-aires et calcifications pulmonaires de la varicelle. *Ann Radiol*, 1976, 19, 437-447.
7. Knyvett AF. - The pulmonary lesions of chickenpox. *Q J Med*, 1966, 35, 313-323.
8. Darke ChS, Middleton RSW. - Calcifications of the lungs after chickenpox. *Br J Dis Chest*, 1967, 61, 198-204.
9. Mackay JB, Cairney P. - Pulmonary calcification following varicella. *N Engl J Med*, 1960, 59, 453-457.
10. Knyvett AF. - Pulmonary calcifications following varicella. *Am Rev Respir Dis*, 1965, 92, 210-214.